

# Biological aspects to enhance fracture healing

Paul L Rodham<sup>1</sup>, Vasileios P Giannoudis<sup>1</sup>, Nikolaos K Kanakaris<sup>1,2</sup> and Peter V Giannoudis<sup>1</sup>

<sup>1</sup>Academic Department of Trauma & Orthopaedics, Leeds General Infirmary, Leeds, United Kingdom of Great Britain and Northern Ireland

<sup>2</sup>Department of Trauma & Orthopaedics, University of Leeds, Leeds, United Kingdom of Great Britain and Northern Ireland

Correspondence should be addressed to P V Giannoudis  
**Email**  
pgiannoudi@aol.com

- The ability to enhance fracture healing is paramount in modern orthopaedic trauma, particularly in the management of challenging cases including peri-prosthetic fractures, non-union and acute bone loss.
- Materials utilised in enhancing fracture healing should ideally be osteogenic, osteoinductive, osteoconductive, and facilitate vascular in-growth.
- Autologous bone graft remains the gold standard, providing all of these qualities. Limitations to this technique include low graft volume and donor site morbidity, with alternative techniques including the use of allograft or xenograft.
- Artificial scaffolds can provide an osteoconductive construct, however fail to provide an osteoinductive stimulus, and frequently have poor mechanical properties.
- Recombinant bone morphogenetic proteins can provide an osteoinductive stimulus; however, their licencing is limited and larger studies are required to clarify their role.
- For recalcitrant non-unions or high-risk cases, the use of composite graft combining the above techniques provides the highest chances of successfully achieving bony union.

## Keywords

- ▶ bone substitute
- ▶ fracture healing
- ▶ non-union
- ▶ bone graft

EFORT Open Reviews  
(2023) **8**, 264–282

## Introduction

Bone grafting is a surgical procedure whereby bone tissue is transplanted from one area to another in order to repair or replace non-viable bone or augment the native healing response (1). Following blood transfusion, bone grafting is the second most commonly performed modality of transplantation, with over two million cases performed annually worldwide (2). Bone grafting is not, however, without complication, with issues including donor site morbidity and potential immune reactivity when allograft and xenograft are utilised (2). Therefore, modern treatment strategies utilise a combination of bone graft and bone substitutes, synthetic materials that can also be inserted into the site of bone loss with or without bone graft to augment healing (3).

Within trauma, there are a number of indications for bone graft, spanning from acute use for traumatic bone defects, as part of staged bone defect management such as that achieved with the masquetelet technique, to augment stability and healing in high-risk fractures such as peri-prosthetic femoral fractures, or in improving the biological activity of an atrophic non-union (4, 5, 6, 7). Irrespective of the aim, successful healing with bone grafts can be considered using the diamond concept

conceptual framework, which states that successful bone healing is dependent on the provision of osteogenic cells, osteoinductive mediators, an osteoconductive matrix, mechanical stability, and adequate vascularity (8, 9). Osteogenicity refers to the provision of osteoprogenitor cells, osteoinductivity to the ability of the graft or substitute to support the proliferation and differentiation of these osteoprogenitor cells, and osteoconductivity to the ability of the substance to facilitate the migration, attachment, and ingrowth of osteoprogenitor cells into the graft (10, 11). These factors must be taken into account when considering the type of graft or substitute utilised to augment bone healing.

This review will summarise the frequently utilised bone graft and substitutes utilised for bone repair, describing their properties, current clinical use, and potential therapeutic targets moving forward.

## Autograft

Autogenous bone grafts, either cortical or cancellous, represent the gold standard against which other grafts are held against (12). Both cortical and cancellous grafts incorporate via a two-phase process, with the early phase consisting of inflammation, revascularisation,

and osteoinduction and a late phase consisting of osteoconduction and graft incorporation with remodelling (13). This process of creeping substitution occurs more quickly in cancellous grafts, with both osteoclasts and osteoblasts resorbing and producing new bone simultaneously over the whole of the graft bed (11). This is in contrast to the incorporation of cortical bone where the dense organized structure necessitates an initial osteoclastic resorptive phase, with osteoblasts subsequently laying down new bone in line with the orientation of the osteoclasts (11). This means that cancellous grafts will incorporate within 6–12 months, whereas cortical grafts will initially weaken and may take years to fully incorporate and return to full strength (14).

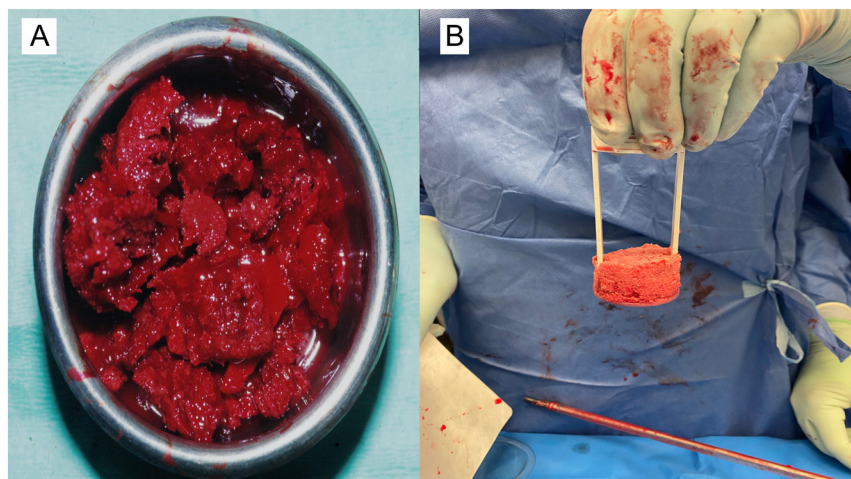
Autogenous bone grafts possess a number of characteristics that establish their role as the gold standard. They possess a high number of osteogenic precursor cells within the graft with no risk of immune reaction facilitating the generation of new bone in the defect (15). They similarly provide an osteoconductive three-dimensional structure onto which new bone can form, and a significant number of osteoinductive growth factors including transforming growth factor-beta (TGF $\beta$ ), bone morphogenetic protein-2,4 (BMP-2,4), and pro-angiogenic factors such as vascular endothelial growth factor (14, 16).

Compared to cortical bone grafts, cancellous bone graft provides a more osteogenic, osteoinductive, and osteoconductive material. They are however limited in terms of their mechanical structure due to the loose trabecular structure (17). Cortical autografts possess greater mechanical stability, but have poorer osteogenic and osteoinductive properties when compared to cancellous graft, and lose a portion of their mechanical strength due to resorption during the initial resorption and revascularisation phase (15). Issues with resorption can be overcome through the use of vascularized cortical

grafts, however, this introduces increased complexity to the operation and increased donor site morbidity to the patient (17). Augmentation of osteogenesis and osteoinduction can be provided through the use of bone marrow aspirate concentrates (BMACs); however, this provides no augmentation of osteoconduction and concerns have been raised regarding heterotopic ossification with the injected marrow migrating away from the injection site when inserted in isolation (18).

The anterior iliac crest remains the most common site for the harvest of autogenous bone grafts, with both cancellous and cortical bone grafts available from this site (19). Other commonly utilised locations include the posterior iliac crest, proximal femur, proximal tibia, distal tibia, calcaneus, and distal radius (20). Where higher volumes of cancellous bone graft are required, the reamer irrigator aspirator system has provided access to the harvest of large volumes (35–90 cc) of bone graft from the long bones, most commonly the femur (21, 22, 23) (Fig. 1).

Cortical bone grafts have been successfully employed in a number of body regions with good results. Hollo *et al.* reported on the use of iliac crest cortical bone graft and plate fixation of clavicle non-union achieving restoration of clavicular length union in 100% of cases (24). Wang *et al.* similarly utilized iliac crest bone graft to support the articular surface in the management of depressed tibial plateau fractures undergoing open reduction and internal fixation. Of the 43 patients who completed follow-up, all patients united, and just two elderly patients lost reduction post fixation (25). The scaphoid represents another common site where cortical bone graft is frequently employed. Huang *et al.* achieved a 94% union rate in their series of 49 scaphoid non-unions treated with iliac crest bone graft and fixation with a Herbert screw (26). Poorer results have been observed when scaphoid non-union is managed with non-vascularized distal radius grafts (73%



**Figure 1**

Autologous cancellous bone graft. (A) Cancellous graft harvested from the posterior iliac crest of the pelvis. (B) Graft harvested from the femoral intramedullary cavity using the RIA device.

union), though this improves with the use of a vascularized distal radius graft (89% union) (27). In a randomized trial of cortical vs cancellous bone graft of scaphoid non-union, cortical graft did not appear to improve union rates (90% cortical vs 94% cancellous) (28).

Due to its improved osteogenicity and osteoinductivity, cancellous bone graft demonstrates a wider range of indications. Cancellous bone graft is the mainstay of the induced membrane technique in the management of critical bone defect. Using this technique, union rates of between 80 and 90% are achievable with defect sizes up to 25cm (7). In addition, cancellous bone graft has demonstrated utility in the management of avascular necrosis of the femoral head where it can be implanted into the femoral head following core decompression (29) to augment healing following high tibial osteotomy for unicompartmental arthritis where it results in fewer complications (30) or for impaction bone grafting in the management of patients with protrusio or with bone defects undergoing complex arthroplasty (31).

Vascularized bone grafts are less commonly performed, with higher morbidity and surgical complexity than non-vascularized grafts. Frequent indications included the management of non-union including vascularized distal radius graft for scaphoid non-union, vascularized fibula or vascularized iliac crest grafts for bone loss, vascularized medial femoral condyle grafts often used for post-traumatic avascular necrosis of the talus or navicular/non-unions of the midfoot, and vascularized fibula graft in the management of avascular necrosis of the femoral head (32, 33, 34). BMAC is also less frequently utilised than other forms of autograft, with its usage mainly in the setting of augmenting fracture healing. Whilst it is suggested that BMAC can both improve and accelerate the rates of healing, there is little clear clinical data available due to discrepancies in the definition of what constitutes treatment-grade BMAC, and therefore, this is a current topic of interest to many studying augmentation of fracture healing (35, 36).

Whilst autograft provides an excellent form of bone graft, there still exist limitations mainly regarding limits of the volume of graft available to harvest, donor site morbidity (pain, infection, haematoma, prolonged wound drainage, sensory loss), and increased magnitude of surgery experienced by the patient as part of the harvesting process (37).

## Allograft

Allograft represents a commonly utilised alternative to autograft, particularly when large volumes of graft are required. Allografts are tissues that have been harvested from one individual and implanted into another individual of the same species (38). There are a number of sources

of allograft including from living donors (femoral head following total hip replacement), following organ retrieval in an organ donor, or those taken post-mortem where the risk of disease transmission is higher (39, 40, 41). Allograft as with autograft can be cortical or cancellous and can also take the form of osteochondral segments for articular defect reconstruction. Incorporation mirrors that of autograft, however with a more significant inflammatory phase due to the increased immunogenicity (38).

Allografts, in most instances, do not contain any live cells and therefore are not osteogenic. They provide an osteoconductive scaffold and structural support to augment healing, and in some instances can exert a minimal osteoinductive potential (11). Demineralised bone matrix (DBM) is a specialised form of allograft that comprises over 50% of allograft use in the USA. It is a highly processed form of allograft that contains collagens and non-collagenous proteins facilitating osteoconduction and also bone morphogenetic proteins (BMPs) and other proteins that provide it with osteoinductive properties (42).

Due to potential pathogen transmission and immune reaction, allograft must be sterilised prior to implantation into the recipient. Initial debridement of soft tissue and washing is performed using ethanol followed by irradiation. Irradiation treatment is performed at a dose of 25 kGy, capable of eliminating most bacteria and viruses, however importantly is not virucidal for HIV and therefore screening procedures of donors remain critical. Freezing can then be performed, either by freezing at 0°C, freezing in liquid nitrogen at -196°C, or by freeze-drying (43, 44). Radiation treatment of frozen bone tends not to affect the mechanical stability; however, irradiation of dried bone will substantially compromise its strength (45). DBM undergoes a similar debridement phase, following which the bone is morselised and subjected to acid demineralisation with hydrochloric acid followed by freeze-drying. The final powder is then combined with a commercially available carrier following which it is ready for use (46).

One of the core usages of allograft is in the management of bone loss when performing complex primary or revision arthroplasty. In this setting, autogenous graft will not be sufficient in volume and therefore structural allograft is instead utilised to manage significant defects, facilitating the restoration of bone stock and mechanical support to the prosthesis. The results in this complex population are promising, with survival rates often quoted between 80 and 90% at 5 years (47). Structural allograft is also of benefit in the management of femoral periprosthetic fractures where the stem remains well fixed. Haddad *et al.* reported on the technique of strut allograft with or without plate fixation achieving a union rate of 98% (48). Similar success was also noted by Font-

Vizcarra *et al.* (49). In addition to managing issues with bone stock in the arthroplasty population, the allograft is frequently employed in the management of defects following oncological procedures. Wisanuyotin *et al.* reported on 47 patients undergoing a limb salvage approach for primary bone tumour, treating an average defect size of 16.2 cm, achieving successful union in 75% of cases, comparable to their cohort who underwent cortical autograft (50).

Allograft can also be utilised in the management of osteochondral defects of the knee which are too large to be managed via other means, or where the underlying bone is also diseased (such as avascular necrosis (AVN)). Current literature suggests 10-year survival rates between 80 and 85%, with between 12 and 18% requiring a revision procedure or arthroplasty following osteochondral allograft (51, 52, 53). Particulate allograft and DBM are less commonly reported on despite their frequent use as an osteoconductive medium or an expander for alternate types of graphs. Most commonly they have been successfully employed in spinal fusion as a graft expander without adversely affecting the fusion rate, in the management of non-union where its efficacy in isolation was lower than that of autograft, and in the management of small bone defects adjacent to periarticular fractures of the tibia, fibula, femur, humerus, forearm, and acetabulum (54).

Whilst allograft represents a useful tool in the management of large bone defects, there are still a number of limitations to its use. First of all, the preparation and storage of allograft necessitate the establishment of a tissue bank, which is both expensive and labour-intensive. The mechanical strength of each graft can be affected by the treatment and therefore one must ensure that adequate stability is provided in addition to the graft. Allograft has limited osteoinductivity and no capacity for osteogenicity, acting only in an osteoconductive manner and therefore these must be supplemented otherwise should the effects be desired. Finally, one must be cognizant of the potential for disease transmission with its use, though modern screening keeps this risk to a minimum (2).

## Xenograft

Xenotransplantation encompasses any procedure that involves the transplantation or infusion of a non-human animal substance into a human, be it in the form of cells, tissue, or fluid (55). Introduced in the 1950s, the majority of xenografts utilised in humans are bovine in source, though their use initially was prevented due to the alpha-Gel epitope expressed on the cell membrane to which humans produce an antibody that leads to graft rejection (56). Prevention of this phenomenon is achieved through the removal of all organic components of the xenograft,

which may be achieved through heat treatment (though this may affect the graft crystalline structure), or hydrothermal hydrolysis with sodium hydroxide and dissolution of the organic component using ethylenediamine or sodium hypochlorite (57).

Interest in xenograft has arisen given the high availability at low cost from healthy donors (55). Current preparation techniques aim to maintain the structure of the graft without removing all osteoinductive growth factors to ensure that the graft retains the properties of osteoconduction and osteoinduction (58). Nonetheless, the initial introduction of these grafts was fraught with high failure rates and complications including failure of integration, graft rejection, and local soft tissue reactions (59, 60, 61, 62).

Commercially available bovine xenografts have been successfully employed in a number of small series spanning the distal radius, tibial plateau, and to reconstruct the donor site following iliac crest harvest (63, 64, 65). A recent review, however, reported that in the majority of series the use of xenograft resulted in an unacceptably high rate of morbidity, thereby recommending against these products use (66). Currently, there are no xenografts that are recommended by the Federal Drug and Administration body (66).

## Growth factors

### *Bone morphogenetic proteins*

Recombinant bone morphogenetic proteins (Rh-BMP) represent the largest subfamily of the TGF $\beta$  family (67). Within the skeletal system, they have a number of functions including the induction of bone and cartilage *in vivo* through stimulation of the proliferation and differentiation of osteoblasts, rendering them osteoinductive (68). Rh-BMPs are produced via recombinant DNA technology, following which they are concentrated and combined with a carrier (e.g. collagen) to improve their handling qualities (69, 70, 71). Commercially available preparations take a powdered form which when combined with saline produces a paste that can be implanted into the bone defect being addressed (42).

At present, the use of Rh-BMPs is restricted, with Rh-BMP-2 licenced only in acute open tibial fractures and anterior lumbar interbody fusion, and Rh-BMP-7 licensed in long bone non-union and posterior lumbar interbody fusion (11). Within the open tibial fracture population, the BESTT trial demonstrated significantly faster fracture healing with reduced reoperation when a Rh-BMP-2 sponge was applied to the fracture site at the time of definitive wound closure (72). In a canine model, Rh-BMP 7 has been demonstrated to accelerate the speed

of incorporation of allograft, with early results in human also proving positive (73).

Rh-BMP 7 has been demonstrated to be efficacious in the long bone non-union population. In a series of 84 long bone non-unions across both the upper and lower limbs, Papanagiotou *et al.* were able to achieve uneventful union in 81% of cases managed with Rh-BMP 7 and bone graft +/- revision fixation at a mean of 5.4 months (74). Of those that failed to heal with this approach, 75% had co-existing infection predisposing to treatment failure. Kanakaris *et al.* reported on a series of 30 patients with aseptic femoral non-union managed with BMP-7 alongside autograft where there was a bone defect greater than 1 cm (12 cases) (75). This included nine cases that had already undergone a failed autograft procedure. Union was achieved in 26 cases (87%) with a median time to union of 6 months. Giannoudis *et al.* also examined the role of BMP-7 combined with autograft in a series of 45 patients with atrophic non-union affecting the femur (19 patients), tibia (19 patients), and humerus (7 patients) (76). In this series, 45% of patients had undergone a previous autograft procedure, however, following treatment with BMP-7 (combined with further autograft in 20 cases), all patients went on to achieve union at a median of 5.5 months. The authors suggested that there may be a synergistic effect between BMP and the autograft, which, however, advocated the performance of larger randomized controlled studies. Friedlaender *et al.* conducted an RCT comparing the use of Rh-BMP 7 with autologous bone graft in the treatment of tibial non-union, establishing that there was no difference in union rate at 9 months (81% Rh-BMP 7 vs 85% autologous bone graft), and a significant reduction in complications relating to donor site which were present in 20% of the autologous bone graft group (70).

Though off-label, BMPs have also been investigated in the management of critical bone defects. In a canine ulna model, Salkeld *et al.* were able to demonstrate that the combination of Rh-BMP 7 with either autograft or allograft lead to faster times to union and a higher mechanical strength by 12 weeks post-operative (77). Haubruck *et al.* performed a single centre analysis of the use of Rh-BMP 2 and Rh-BMP 7 combined with autologous bone grafting as part of the management of lower limb long bone non-union (both single and two-stage), establishing a 91% consolidation rate when Rh-BMP 2 was utilised, compared to just 58% with Rh-BMP-7 (78). They did not, however, establish a control group when BMP was not utilised. Similar advantages to the use of BMP 2 over BMP 7 were seen by Conway *et al.* (79).

Whilst BMPs show promise, there are a number of drawbacks to their use. Containment of BMPs can be challenging, with a propensity to migrate away from their site of application. This can lead to complications including

ectopic bone formation which has been demonstrated to be problematic at a number of sites including the C-spine, tibial plateau and the pelvis (80, 81). The processing costs similarly make BMP products expensive, often restricting their usage to resistant or high risk cases (42). Finally, it should be noted that BMP-7 has been withdrawn from the market recently by Olympus biotec, a decision purely based on commercial reasons rather than lack of effectiveness or safety concerns.

#### *Platelet-rich plasma*

Platelet-rich plasma (PRP) has been an ongoing topic of interest in bone healing given its critical role in the native response to fracture where they recruit mesenchymal stem cells (MSCs), secrete growth factors, and promote angiogenesis (82, 83). When utilised *ex-vivo*, they have been demonstrated to increase osteoblast proliferation and subsequent osteoid deposition, hence rendering these products osteoinductive (84).

PRP is produced through the process of differential centrifugation which separates components of the patient's blood based on differing specific gravities. Whole blood is initially centrifuged with the resulting supernatant containing high concentrations of platelets and white blood cells. The supernatant is subsequently re-centrifuged following which a small platelet-rich pellet forms in the base of the tube. The supernatant is removed and the pellet is resuspended in a small volume of plasma to produce PRP. This process is simplified through the use of commercially available PRP harvesting preparations that can harvest PRP from between 20 and 60 mL of whole blood (85). The platelet count within these preparations generally varies based on the volume of blood utilised, the speed of each centrifugation, and the duration of centrifugation; however, PRP is generally defined to contain  $1.25\text{--}1.5 \times 10^6$  platelets/mL (86).

Data regarding the use of PRP to augment bone healing following trauma is relatively limited, with a recent systematic review finding only nine studies (eight randomised) examining its use (87). In this review, PRP was demonstrated to produce higher union rates when utilised at the time of ORIF of acute scaphoid fractures, however, demonstrated no differences in the union rates when applied to fractures of the femur, distal radius, hip, calcaneus, or mandible. As with many studies of this type, limitations included differing methodologies in producing PRP with none of the included studies defining the concentration of platelets utilised (87, 88).

Within non-union surgery, the use of PRP has demonstrated promising results. PRP can be utilised as an osteoinductive substance added to autologous graft, demonstrating higher healing rates and faster union times across a number of both randomised and non-randomised studies (89, 90, 91, 92). PRP can also be employed as a

percutaneous injection into long bone non-union, particularly in comorbid patients where the risks of more extensive surgery are high, with series demonstrating healing rates of between 65 and 93% utilising this technique (93, 94, 95, 96).

Although promising, current research into PRP is limited by the lack of a clear definition of the product, and varying techniques in its production. Moving forward further randomised studies are required to validate its use, with a clear discussion of centrifugation techniques, platelet concentration achieved, and volume utilised.

### Peptides

In addition to Rh-BMP, recombinant DNA technology has raised interest in a number of naturally occurring peptides that have been utilised to augment bone healing (97).

The most studied of these molecules is parathyroid hormone<sub>1-34</sub> peptide (PTH<sub>1-34</sub>). This synthetic analogue consists of the first 34 amino acids of the native 84 amino acid molecule, is administered as a subcutaneous injection (under the trade name teriparatide), and is demonstrated to stimulate osteoblast proliferation and differentiation, rendering it osteoinductive (98). Whilst its main usage comes in the management of osteoporosis, there is weak evidence that PTH<sub>1-34</sub> may be efficacious for a number of indications including the management of stress fractures, sacral insufficiency fractures, hip fractures, periprosthetic fractures, and long bone non-union (99, 100, 101, 102, 103, 104, 105).

Parathyroid hormone-related protein (PTHrP) is a much larger protein (139–175 amino acids) that has been demonstrated to be critical in both the development of the fetal skeleton and osteoblastic activity in fracture healing (106, 107, 108). Animal studies on this topic suggest that the use of synthetic PTHrP can enhance fracture healing resulting in a higher osteoblast concentration with larger callus formation, a higher stiffness and resistance to torque than those individuals where PTHrP was not utilised (109, 110). Whilst the preclinical results are promising and the use of PTHrP in osteoporosis demonstrated to be effective, there are no human studies assessing PTHrP in fracture healing, and therefore, its use is not currently supported (111).

A number of additional peptides provide potential future targets, albeit with limited animal-based evidence available. Calcitonin gene-related peptide is usually found in nerve endings, periosteum, and bone marrow; has been demonstrated to increase in expression at times of fracture repair; and result in increased bone formation during fracture healing in mice (112, 113, 114). This molecule may play a role in nerve in-growth during fracture healing, the absence of which has been demonstrated to preclude towards non-union (115). *In vitro* studies have demonstrated that osteogenic

growth peptide (OGP) can regulate osteoprogenitor cell differentiation and proliferation resulting in higher alkaline phosphatase activity, osteocalcin secretion, and matrix mineralisation (116, 117, 118). In animal models, systemic administration of OGP has been demonstrated to result in greater callus formation, whilst local administration to segmental bone defect via a carrier has been demonstrated to result in higher bone volume production at an accelerated rate (119, 120). Despite promising pre-clinical data, there does not yet exist any clinical data in humans, and therefore, further research is required before routine use of these molecules can be encouraged.

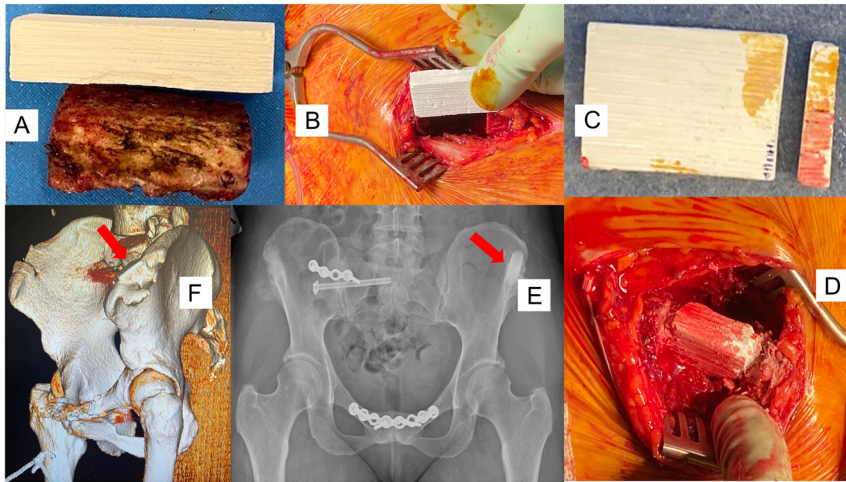
### Synthetic bone substitutes

Synthetic bone substitutes represent an attractive option in augmenting fracture healing, providing mainly an osteoconductive material without donor site morbidity or the potential immune and infective complications posed by allograft (121) (Fig. 2). The main synthetic bone substitutes are presented later.

#### Tricalcium phosphate

$\beta$ -Tricalcium Phosphate ( $\beta$ TCP) is a synthetic compound containing both calcium and phosphate, which is osteoconductive and undergoes cell-mediated resorption (122). It can be manufactured by three main techniques: (i) solid-state reaction of a calcium-rich and a phosphate-rich phase, (ii) thermal conversion of amorphous calcium phosphate, and (iii) direct precipitation in an organic media such as ethylene glycol (123, 124, 125). Typically,  $\beta$ TCP is available as a paste; however, it can be manufactured into scaffolds through extrusion printing with changes to its topography and porosity utilised to manipulate its osteoconductive and cell homing properties (122).

$\beta$ TCP is mechanically weaker than cancellous bone, and has a reported resorption time of between 13 and 20 weeks which means the operator must be cautious as it may resorb prior to substitution by native bone (121). This has, however, more recently been challenged with the synthetic graft remaining *in situ* at over a year post tibial plateau fixation (126). Within trauma,  $\beta$ TCP has proved an effective graft substitute at a number of sites including the humerus, elbow, forearm, distal radius, tibial plateau, distal femur, and tibial plafond (126, 127, 128, 129). It results in minimal post-operative articular displacement when utilised to fill metaphyseal defects in periarticular fractures and is reported to have good to excellent incorporation in 75% of cases (127, 129). In the augmentation of healing of proximal tibial osteotomies,  $\beta$ TCP was demonstrated to be non-inferior to autologous bone graft, albeit with low overall numbers (130).



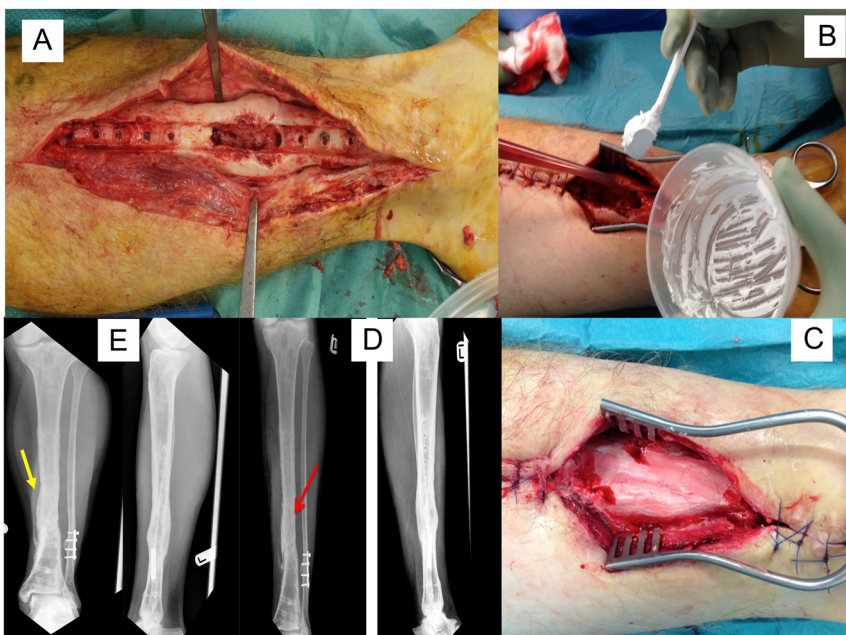
**Figure 2**

Demonstration of the use of a synthetic material Greenbone block for defect treatment of the pelvic iliac crest. (A) Comparison between the tricortical iliac crest harvested for a pubic symphysis fusion with the synthetic greenbone block. (B) Intra-operative picture showing the greenbone next to the iliac crest defect prior to implantation. (C) Cutting with an electric saw the green bone block scaffold to appropriate length. (D) Implantation of the green bone by press fitting application within the iliac crest defect. (E) AP pelvic radiograph showing the integration of the green bone scaffold at 12-month follow-up (red arrow). (F) Pelvic 3D model showing incorporation of the green bone scaffold within the iliac crest defect (red arrow).

*Calcium sulphate*

Calcium sulphate, also known as plaster of Paris ( $\text{CaSO}_4$ ), is an osteoconductive molecule that can be formed into an injectable fluid or hard pellets (4). It is manufactured through the dehydration of the naturally occurring mineral calcium sulphate dihydrate ( $\text{CaSO}_4 \cdot 2\text{H}_2\text{O}$ ) (131). Once set, it produces a structural graft with a compressive strength similar to cancellous bone that undergoes rapid resorption over a period of 4–12 weeks and can be combined with antibiotics increasing interest in these molecules where fracture-related infection is present (11). The most commonly encountered commercially available products include osteoset, stimulan, and cerament (132) (Fig. 3).

When combined with antibiotics such as gentamicin, calcium sulphate provides a valuable tool in providing a high concentration of local antimicrobial that elutes over a period of 4 weeks (133). The use of local antibiotics has revolutionised the management of long bone fracture-related infection, reducing recurrence rates from 30 to 40%, to less than 10% (134, 135, 136). Calcium sulphate bone substitutes have also been demonstrated to be efficacious when managing small bone defects (<1 cm), with graft resorption and new bone incorporation occurring over a course of 6 months with good clinical results (137). For larger defects, the clinical evidence is more limited and therefore traditional techniques should be employed.



**Figure 3**

Application of calcium sulphate (stimulant) for the treatment of a tibial partial bone defect following debridement for late presentation of infection after union that required also removal of the plate. (A) Intra-operative picture showing the footprint of the plate after removal and the defect created following debridement of the infected bone area. (B) Intra-operative picture showing the application of stimulant to the defect area. (C) Intra-operative picture with covering of the defect area with stimulant. (D) AP and lateral tibial radiographs at 8 weeks showing that the defect is healing. (E) AP and lateral tibial radiographs 16 weeks later showing complete healing of the defect area.

Calcium sulphate substitutes can be associated with a number of local complications including skin reaction and wound leak, although these complications are increasingly less common with the modern generation of products (138).

### Hydroxyapatite

Hydroxyapatite ( $\text{Ca}_{10}[\text{PO}_4]_6[\text{OH}]_2$ ) is a naturally occurring calcium apatite that forms the main constituent of the mineral component of bone. Its large pores allow for the attachment and interdigitation of osteoprogenitor cells alongside vascular ingrowth making it osteoconductive (4). It is readily resorbable, being replaced by the native bone through substitution. When combined with ceramics it is much more slowly resorbed (up to 10 years), and whilst mechanically strong in compression and tension, remains brittle therefore acting as a potential stress concentrator (139).

Commercial hydroxyapatite is either bovine-derived, or synthetic with its main current clinical usage in dentistry either to augment the integration or in the management of small bony defects (140). For the management of small bone defects within the field of dentistry, hydroxyapatite has been demonstrated to be more efficacious than alternate bone substitutes such as  $\beta$ TCP (141). Though promising, animal studies have suggested that hydroxyapatite is inferior to autologous bone graft in the management of bone defects, likely due to its lack of osteoinductive activity (142). The ability of hydroxyapatite to produce similar results to autologous bone graft in terms of graft incorporation and restoration of mechanical strength occurs when an osteoinductive protein (recombinant human osteogenic protein-1) is added (142).

Within orthopaedic trauma, the main use of hydroxyapatite is in the coating of implants where it has been demonstrated to improve the shear strength and resistance to pull out with greater bone ongrowth (143). This is particularly demonstrated with the use of hydroxyapatite half-pins as part of an external fixation construct whereby the extraction torque of hydroxyapatite-coated pins is nearly 100 $\times$  that of non-coated half-pins, and rates of loosening reduce from 80% to just 4% (144).

### Bioglass

Bioglass is a specialised form of glass that contains a high molar ratio of calcium, which promotes apatite crystals rendering the substance osteoconductive (145). They are formed through the heating of phosphor-silicate materials with calcium and sodium oxides which are subsequently submerged in water causing crystallisation and formation of the glass (146). The product can be made into putty for simple application or manipulated into complex 3D structures through extrusion printing, with the ability

to vary the pore size to provide topographic signals to osteogenic cells (145).

Cortoss was one of the first commercially available Bioglass products, applied as a structural graft following kyphoplasty given its compressive strength similar to that of cortical bone. Cortoss proved to be an effective graft with little post-procedure collapse and positive clinical results in terms of pain reduction with few complications (147). Bioglasses have been demonstrated to be antibacterial, raising interest in their use in the treatment of fracture-related infections. Whilst the clinical series are small, results with Bioglass are promising with infection suppression rates of greater than 90% when utilised as part of dead space management following bone debridement (148, 149, 150, 151).

Bioactive glass has also been utilised in the management of post-traumatic bone defects. Perna *et al.* utilised BAG-S53P4 in the management of depressed tibial plateau fractures, with no difference in secondary collapse observed when compared to iliac crest autograft (152). Similar results were observed by Heikkilä *et al.* in their randomized controlled study comparing S53P4 to iliac crest graft in tibial plateau fractures, again noting no difference in secondary displacement between the groups, despite higher initial displacement in the iliac crest group (153).

Clinical data regarding the utilisation of bioglass in Orthopaedic trauma remain limited, and there are a number of limitations to its use. It is a brittle material with slow resorption, producing a theoretical risk of fracture although the long-term follow-up in early clinical data is promising (154). It also exerts local pH changes that induce cytotoxicity *in vitro*, though clinically relevant effects have not yet been observed (155).

### Coralline

Coral is a limestone structure created by marine invertebrates that extract calcium and phosphorous from the sea. It shares a similar structure to the cancellous bone which raised interest in the potential applications of coral in the human skeleton (156). Coralline when implanted into bone is biocompatible, facilitates vascular ingrowth, and is osteoconductive to the native bone-forming cells (157). Resorption of coral, as with native bone, is carried out by osteoclasts and the action of carbonic anhydrase (158). Currently, there are two commercially available coralline bone substitutes: coral in their native form with Biocoral, and a hydroxyapatite product derived from coral in the form of Pro Osteon (159).

*In vitro* corals have been demonstrated to facilitate the attachment, proliferation, and differentiation of MSCs, performing better than alternatives such as bone allograft and DBM (160, 161, 162). In addition to cell kinetics, corals result in high levels of alkaline phosphatase production,



calcium deposition, and osteogenic gene expression (163, 164, 165). The efficacy of coralline-based substitutes was subsequently validated in animal models, where it has been demonstrated to be non-inferior to the autologous bone in bone defects in dog (166). Concerns were, however, raised at this stage with failure of the graft to fully incorporate, with bone instead growing around the coralline material (167).

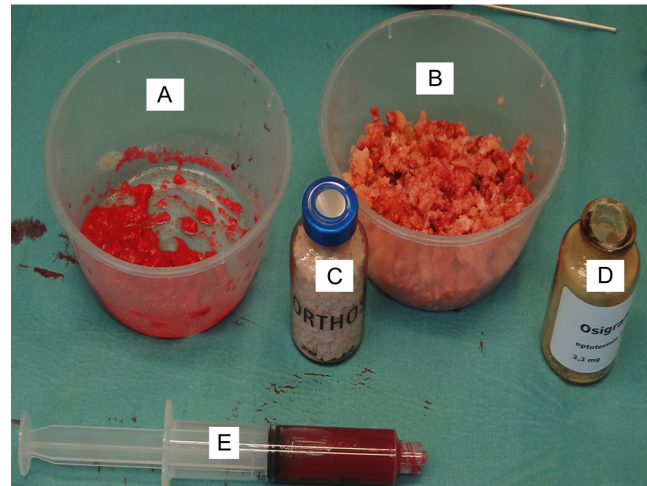
In humans, initial problems were also seen with incorporation and containment of the graft material when utilised in the case of hindfoot arthrodesis, albeit with satisfactory clinical results (168). These problems were not, however, seen in the tibial plateau fracture population where coralline graft performed similarly to autologous bone graft (169). Successful consolidation was achieved in five cases of ulna non-union with the use of Biocoral, whereas a high failure rate was observed when utilising this substance to manage acute scaphoid fractures (159).

Overall, the literature supporting the use of coralline grafts is limited, with only a small volume series spanning a number of body areas available. The resorption of coral is unpredictable, and where ingrowth does not occur, coral can act as a physical barrier to bone healing. Results appear to be site-specific, with a suggestion for poorer bone healing in areas with poor blood flow.

### Composite grafts

The term ‘composite graft’ refers to the process of combining different available materials in order to increase the biological properties and the volume of bone graft (170). Materials that can be used within this concept include autologous bone graft, allograft, BMP-2, PRP, bone marrow aspirate, xenograft granules, and synthetic granules either existing in isolation or attached to collagen matrices (Fig. 4) (171). This approach has been popularised with the conceptual framework of the diamond concept for optimum biological stimulation for bone-guided regeneration and generally speaking is also known as ‘polytherapy’ (Fig. 5) (8).

The efficacy of polytherapy via composite grafts was recently reported by Giannoudis *et al.* (172). They examined 64 patients (34 males) with a mean age of 45 years (17–83) undergoing treatment for non-union of the femur (35), tibia (22), humerus (3), radius (2), or clavicle (2). Through the application of the diamond concept utilising a polytherapy approach, the authors were able to achieve union in 98% with a mean time to union of 6 months. The authors of this study believe that such a successful union rate was achieved through the local provision of the essential constituents for bone repair and recommend that such a strategy is considered in such cases where poor bone healing is anticipated. Further



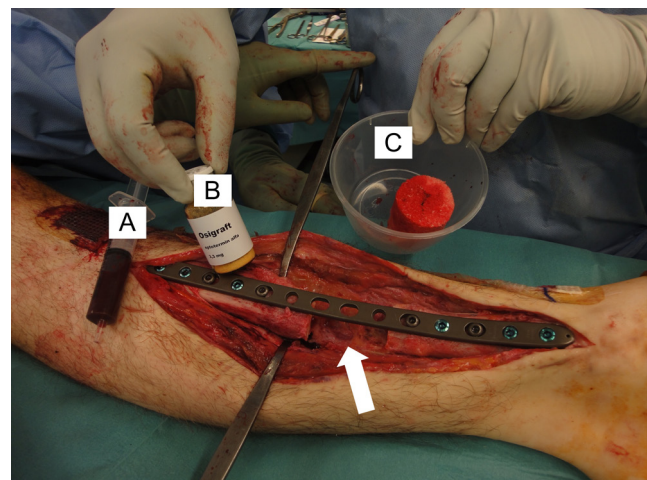
**Figure 4**

Graft materials used for composite grafting. (A) Autologous graft. (B) Allograft. (C) Xenograft (Orthos). (D) BMP-7. (E) Bone marrow aspirate.

high-volume studies should aim to further establish the effectiveness of composite grafting in this patient cohort.

### Discussion

Bone is a constantly evolving tissue, responding to the forces placed upon it in order to maximise efficiency in supporting the functions of the body (173, 174). When injured it is primed with an intrinsic capacity for repair (175). Under certain conditions, there may be a need to try and enhance fracture repair, be that in the context of high-risk injuries, such as those with bone loss, or in the case



**Figure 5**

Treatment of a tibial defect utilising the polytherapy approach. Implantation of (A) concentrated bone marrow aspirate (progenitor cells), (B) BMP-7, and (C) RIA graft.

of non-union where the fracture will fail to heal without further intervention.

Initial assessment of progress towards union must always consider the mechanics of the device employed, and if the mechanical environment is appropriate to facilitate bone healing as intended by the operating surgeon, be that via primary or secondary healing. From the interfragmentary strain concept popularised by Perren, we are aware that the tissues within the fracture site have differing strain tolerances, with the progression from granulation tissue through to the formation of bone dependent on the provision of an appropriate mechanical environment (176). Both too rigid and too flexible a fixation will preclude to non-union, with the bone healing unit often intact and biological non-union a relative rarity in isolation (177). As such alteration of the mechanics is a frequent aim of non-union surgery, with techniques including dynamization, percutaneous strain reduction screws, exchange nailing to a larger diameter nail, or the Ilizarov technique (178, 179, 180, 181). With techniques such as exchange nailing, in addition to improving the mechanical environment, there is a significant biological stimulus with the reaming process resulting in the local influx of growth factors including TGFβ, platelet-derived growth factor, and insulin-like growth factor (182).

There also exist non-operative techniques to stimulate the biology of non-healing fractures, particularly in comorbid patients who are at high risk from an anaesthetic point of view. Low-intensity pulsed ultrasound (LIPUS) is a non-invasive technique that works through stimulating osteoblastic activity. Compared to controls, patients managed with LIPUS generate greater osteoid thickness with higher callus volume (183). When utilised to augment healing in acute fractures, LIPUS has been demonstrated to reduce the healing time of fractures by 30–40%; whilst in the management of non-union, LIPUS has been demonstrated to achieve union in 82% of cases (184, 185).

Where surgical augmentation of biology is required, autologous bone grafting remains the gold standard, with or without further augmentation with osteoinductive factors. In a review of 182 cases of long bone non-union, Flierl *et al.* demonstrated a significant shorter time to union when utilising autograft (198 days) compared to allograft (416 days) and combined allograft and autograft (389 days) (186). The autograft group also required fewer revision surgeries (17% vs 47% and 25%, respectively) and had the lowest rates of post-operative infection. When bone grafting is combined with the provision of osteoinductive mediators and an appropriate mechanical environment as per the diamond concept, the rate of treatment success in the management of long bone non-union is between 89 and 100%, compared to just 44 and 90% when this concept is only partially applied (9).

Further complexity is added to the management of bone healing when critical-sized bone defects are present, defined as those defects that would not heal spontaneously within the patient's lifetime (187). In these situations, the two main techniques employed are the masquelet technique and bone transport.

The masquelet technique is a two-stage technique whereby an initial debridement is undertaken with a cement spacer placed into the defect and appropriate stabilisation of the bone provided. A vascularised membrane forms around the spacer, and following a period of 6–8 weeks, this membrane is opened, the cement removed, and bone graft inserted with or without additional adjuncts (such as BMAC and BMP) (7). In a recent series examining this technique, union was achieved in 88% of cases with an average time to union of 8 months (188). Given the volume of graft required, consideration should be given to the harvest site with RIA reaming of the contralateral femur (up to 90 cc) or the posterior iliac crest (up to 88 cc) providing the highest volumes of graft (189). The graft volume can be further expanded through the use of a bone substitute as a graft expander either synthetic or bovine (e.g. Vitoss/greenbone or orthos), and further osteogenic/osteoinductive mediators can be provided through the addition of BMAC and BMP (188).

Bone transport utilises an external fixation device to transpose a bone segment via a corticotomy at a rate of 1 mm/day. New bone forms within the defect created, followed by the bone defect gradually reducing until the bone ends dock and are compressed (190). Alternatively,



**Figure 6** Demonstration of enhancing the biological properties of allograft material. (A) Femoral head allograft. (B) Processing of femoral head into bone chips. (C) Loading of allograft chips with autologous PRP and concentrated bone marrow aspirate. (D) Difference in the macroscopic appearance of the allograft after enhancement appearing more viable (red) possessing inductivity and cellularity.

**Table 1** Bone graft materials assigned into different categories. Category I and II graft materials: Used to promote healing in non-unions, bone voids, bone defects, fusions of joints (arthrodesis). Category III and IV materials: Used to provide structural support in articular impaction injuries, provide healing for bone voids, fusion of joints, osteotomies, be used as graft expanders and for composite grafting.

Category	Bone graft materials
I: Harvested bone graft materials	<ol style="list-style-type: none"> <li>1. Autologous</li> <li>2. Allogenic</li> <li>3. Xenograft</li> <li>4. Bone marrow aspirate</li> </ol>
II: Inductive materials – Growth factors	<ol style="list-style-type: none"> <li>1. BMPs</li> <li>2. PRP</li> <li>3. Demineralised bone matrix</li> </ol>
III: Ceramic based bone graft substitutes (scaffolds)	<ol style="list-style-type: none"> <li>1. Calcium hydroxyapatite</li> <li>2. Tricalcium phosphate</li> <li>3. Calcium sulphate</li> <li>4. Injectable ceramic cements</li> <li>5. Bioglass</li> </ol>
IV: Miscellaneous	<ol style="list-style-type: none"> <li>1. Coralline - HA</li> </ol>

the limb can be acutely shortened and re-lengthened through a distant corticotomy (191). Results with this technique are positive with union rates around 90% following an average time frame of 10–11 months (192). Good to excellent functional rates are achieved in over 80% of cases though the treatment morbidity can be high with an average of 1.22 complications per patient including pin tract infections, joint stiffness, and refracture (192). The

advent of cable transport has further expanded the role of bone transport to larger defects or those with poor quality soft tissues and also facilitates improved weight bearing with reduced pain during the transport phase (193, 194).

The concept of composite grafting (polytherapy) appears to be a sensible option for one to consider particularly for the treatment of recalcitrant non-unions, critical size bone defects, and in patients with compromised

Substance	Osteogenic	Osteoconductive	Osteoinductive	Structural	Vascularised	Disadvantages
Cancellous autograft	+++	+++	+++	No	No	Limited volume Donor site morbidity Increased surgical burden
Cortical autograft	+	++	+	Yes	No	Limited volume Donor site morbidity Increased surgical burden
Bone marrow aspirate	+++	-	++	No	No	Donor site morbidity Difficult to contain at site of injection
Vascularised cortical graft	++	++	+	Yes	Yes	Donor site morbidity More complex surgery Increased surgical burden
Allograft	-	++	-	Yes	No	Cost Laborious procedures Reduced strength Limited osteoinduction Infection risk
Allograft Demineralized bone matrix	-	++	++	No	No	Varying osteoinductivity depending on harvest
Xenograft	-	++	Change color to red	Can be	No	
Bone morphogenetic protein	-	-	++	No	No	Increased cost Limited licensing Complications when used around joints/nerves
Platelet rich plasma	-	-	++	No	No	Lack of consistency in preparation Limited evidence
Peptides	-	-	+	No	No	Limited evidence in humans
Tricalcium phosphate	-	+	-	Yes	No	Limited osteoinductivity
Calcium sulphate	-	+	-	Yes - short term	No	Rapid resorption Osteoconductive only Wound leak
Hydroxyapatite	-	++	-	Yes	No	Slow resorption Osteoconductive only
Bioglass	-	+	-	Can be	No	Slow resorption Difficult to shape Cytotoxicity due to high local calcium concentration Brittle
Coralline	-	++	-	-	-	Poor resorption Difficult to contain Limited data

**Figure 7**

Overview of materials used in the clinical setting based on their properties and limitations of their use.

biological host responses such as smokers, diabetics, and arteriopathies (peripheral vascular disease). Enhancing the biological properties and potency of a graft material appears to generate powerful osteogenic and angiogenic conditions mediating a timely if not faster completion of the desirable healing processes (Fig. 6). However, it is imperative for one not to forget that for any graft material to successfully work, the bed of implantation must be aseptic, vascular, and possessing adequate mechanical stabilisation.

The selection and/or combination of the graft material to be used is the surgeon's choice who must analyse the conditions of the local environment, the sequelae of the original injury to the affected extremity (for instance, if it was an open fracture or a crush injury: what is the state/vitality of the muscular bed, periosteum, limb vascularity, etc), the existence of underlying comorbidities of the host (patient) and the anticipated volume of graft material that will be needed. Only then the correct decision will be taken for the right patient and the right indication. Table 1 shows a summary of the different bone graft materials that can be considered for implantation grouped into different categories and how the different graft materials could be used in isolation or in combination for bone grafting procedures. Figure 7 provides a summary of their properties and limitations.

## Conclusion

Augmentation of bone healing remains a complex problem, with a number of different potential solutions. When required, each case must be carefully considered to establish which factors are deficient, and therefore what stimulus is required be that mechanical or biological. The gold standard for augmenting bone healing remains autologous bone graft; however, limitations in volume mean that combination with other techniques is often required to achieve successful union. Appropriate graft selection requires that the operating surgeon is familiar with the properties they possess as well as their limitations in order to select the correct material for the right indication.

### ICMJE conflict of interest statement

The authors declare that there is no conflict of interest that could be perceived as prejudicing the impartiality of the research reported.

### Funding statement

This work did not receive any specific grant from any funding agency in the public, commercial, or not-for-profit sector.

### Originality statement

This article has not been previously published nor is under consideration, either in full or in part, by any other journal

### Brief description

The presented article provides an up-to-date review of the most commonly employed substances employed in order to augment fracture healing, spanning from bone graft, to bone substitutes, to osteoinductive synthetics. It aims to provide the readership of *EFORT Open Reviews* with a comprehensive summary of bone substitutes, their mechanism of action and their current clinical evidence.

## References

- Fesseha H & Fesseha Y.** Bone grafting, its principle and application: a review. *Osteology and Rheumatology* 2020 **1** 43–50. (<https://doi.org/10.17140/ORHOJ-1-113>)
- Campana V, Milano G, Pagano E, Barba M, Cicione C, Salonna G, Lattanzi W & Logroscino G.** Bone substitutes in orthopaedic surgery: from basic science to clinical practice. *Journal of Materials Science. Materials in Medicine* 2014 **25** 2445–2461. (<https://doi.org/10.1007/s10856-014-5240-2>)
- Schlickewei W & Schlickewei C.** The use of bone substitutes in the treatment of bone defects – the clinical view and history. *Macromolecular Symposia* 2007 **253** 10–23. (<https://doi.org/10.1002/masy.200750702>)
- Wang W & Yeung KWK.** Bone grafts and biomaterials substitutes for bone defect repair: a review. *Bioactive Materials* 2017 **2** 224–247. (<https://doi.org/10.1016/j.bioactmat.2017.05.000>)
- Azi ML, Aprato A, Santi I, Kfuri MJ, Masse A & Joeris A.** Autologous bone graft in the treatment of post-traumatic bone defects: a systematic review and meta-analysis. *BMC Musculoskeletal Disorders* 2016 **17** 465. (<https://doi.org/10.1186/s12891-016-1312-4>)
- Tsiridis E, Spence G, Gamie Z, El Masry MA & Giannoudis PV.** Grafting for periprosthetic femoral fractures: strut, impaction or femoral replacement. *Injury* 2007 **38** 688–697. (<https://doi.org/10.1016/j.injury.2007.02.046>)
- Giannoudis PV, Faour O, Goff T, Kanakaris N & Dimitriou R.** Masquelet technique for the treatment of bone defects: tips-tricks and future directions. *Injury* 2011 **42** 591–598. (<https://doi.org/10.1016/j.injury.2011.03.036>)
- Giannoudis PV, Einhorn TA & Marsh D.** Fracture healing: the diamond concept. *Injury* 2007 **38**(Supplement 4) S3–S6. ([https://doi.org/10.1016/S0020-1383\(08\)70003-2](https://doi.org/10.1016/S0020-1383(08)70003-2))
- Andrzejowski P & Giannoudis PV.** The “diamond concept” for long bone non-union management. *Journal of Orthopaedics and Traumatology: Official Journal of the Italian Society of Orthopaedics and Traumatology* 2019 **20** 21. (<https://doi.org/10.1186/s10195-019-0528-0>)
- Albrektsson T & Johansson C.** Osteoinduction, osteoconduction and osseointegration. *European Spine Journal* 2001 **10**(Supplement 2) S96–101. (<https://doi.org/10.1007/s005860100282>)
- Roberts TT & Rosenbaum AJ.** Bone grafts, bone substitutes and orthobiologics: the bridge between basic science and clinical advancements in fracture healing. *Organogenesis* 2012 **8** 114–124. (<https://doi.org/10.4161/org.23306>)
- Burchardt H.** The biology of bone graft repair. *Clinical Orthopaedics and Related Research* 1983 **174** 28–42. (<https://doi.org/10.1097/00003086-198304000-00005>)
- Cypher TJ & Grossman JP.** Biological principles of bone graft healing. *Journal of Foot and Ankle Surgery* 1996 **35** 413–417. ([https://doi.org/10.1016/S1067-2516\(96\)80061-5](https://doi.org/10.1016/S1067-2516(96)80061-5))
- Burchardt H.** Biology of bone transplantation. *Orthopedic Clinics of North America* 1987 **18** 187–196. ([https://doi.org/10.1016/S0030-5898\(20\)30382-5](https://doi.org/10.1016/S0030-5898(20)30382-5))
- Pape HC, Evans A & Kobbe P.** Autologous bone graft: properties and techniques. *Journal of Orthopaedic Trauma* 2010 **24**(Supplement 1) S36–S40. (<https://doi.org/10.1097/BOT.0b013e3181cec4a1>)

- 16. Schmidmaier G, Herrmann S, Green J, Weber T, Scharfenberger A, Haas NP & Wildemann B.** Quantitative assessment of growth factors in reaming aspirate, iliac crest, and platelet preparation. *Bone* 2006 **39** 1156–1163. (<https://doi.org/10.1016/j.bone.2006.05.023>)
- 17. Chiarello E, Cadossi M, Tedesco G, Capra P, Calamelli C, Shehu A & Giannini S.** Autograft, allograft and bone substitutes in reconstructive orthopedic surgery. *Aging Clinical and Experimental Research* 2013 **25**(Supplement 1) S101–S103. (<https://doi.org/10.1007/s40520-013-0088-8>)
- 18. Khan SN, Cammisia FPJ, Sandhu HS, Diwan AD, Girardi FP & Lane JM.** The biology of bone grafting. *Journal of the American Academy of Orthopaedic Surgeons* 2005 **13** 77–86. (<https://doi.org/10.5435/00124635-200501000-00010>)
- 19. Ahlmann E, Patzakis M, Roidis N, Shepherd L & Holtom P.** Comparison of anterior and posterior iliac crest bone grafts in terms of harvest-site morbidity and functional outcomes. *Journal of Bone and Joint Surgery. American Volume* 2002 **84** 716–720. (<https://doi.org/10.2106/00004623-200205000-00003>)
- 20. Myeroff C & Archdeacon M.** Autogenous bone graft: donor sites and techniques. *Journal of Bone and Joint Surgery. American Volume* 2011 **93** 2227–2236. (<https://doi.org/10.2106/JBJS.J.01513>)
- 21. Dawson J, Kiner D, Gardner W 2nd, Swafford R & Nowotarski PJ.** The reamer-irrigator-aspirator as a device for harvesting bone graft compared with iliac crest bone graft: union rates and complications. *Journal of Orthopaedic Trauma* 2014 **28** 584–590. (<https://doi.org/10.1097/BOT.000000000000086>)
- 22. Cox G, Jones E, McGonagle D & Giannoudis PV.** Reamer-irrigator-aspirator indications and clinical results: a systematic review. *International Orthopaedics* 2011 **35** 951–956. (<https://doi.org/10.1007/s00264-010-1189-z>)
- 23. Han F, Peter L, Lau ETC, Thambiah J, Murphy D & Kagda FHY.** Reamer Irrigator Aspirator bone graft harvesting: complications and outcomes in an Asian population. *Injury* 2015 **46** 2042–2051. (<https://doi.org/10.1016/j.injury.2015.07.027>)
- 24. Hollo D, Kolling C, Audigé L, Moro F, Rikli D & Müller AM.** Plating and cortical bone grafting of clavicular nonunions: clinical outcome and its relation to clavicular length restoration. *JSES International* 2020 **4** 508–514. (<https://doi.org/10.1016/j.jseint.2020.04.002>)
- 25. Wang Z, Zhu Y, Deng X, Xin Xing, Tian S, Fu L, Yan X, Chen W, Hou Z & Zhang Y.** Structural bicortical autologous iliac crest bone graft combined with the tunnel bone tamping method for the depressed tibial plateau fractures. *BioMed Research International* 2021 **2021** 1249734. (<https://doi.org/10.1155/2021/1249734>)
- 26. Huang YC, Liu Y & Chen TH.** Long-term results of scaphoid nonunion treated by intercalated bone grafting and Herbert's screw fixation—a study of 49 patients for at least five years. *International Orthopaedics* 2009 **33** 1295–1300. (<https://doi.org/10.1007/s00264-008-0663-3>)
- 27. Ribak S, Medina CEG, Mattar RJ, Ulson HJR, Ulson HJR & Etchebehere M.** Treatment of scaphoid nonunion with vascularised and nonvascularised dorsal bone grafting from the distal radius. *International Orthopaedics* 2010 **34** 683–688. (<https://doi.org/10.1007/s00264-009-0862-6>)
- 28. Hegazy G, Massoud AH, Seddik M, Abd-Elghany T, Abdelaal M, Saqr Y, Abdelaziz M, Zayed E & Hassan M.** Structural versus nonstructural bone grafting for the treatment of unstable scaphoid waist nonunion without avascular necrosis: a randomized clinical trial. *Journal of Hand Surgery* 2021 **46** 462–470. (<https://doi.org/10.1016/j.jhsa.2021.01.027>)
- 29. Kang JS, Moon KH, Park SR, Kang SB, Park HB & Lee SH.** Clinical results of autoiliac cancellous bone graft combined with implantation of autologous bone marrow cells for osteonecrosis of the femoral head. *Journal of the Korean Orthopaedic Association* 2008 **43** 1–8. (<https://doi.org/10.4055/jkoa.2008.43.1.1>)
- 30. Cho SW, Kim DH, Lee GC, Lee SH & Park SH.** Comparison between autogenous bone graft and allogeneous cancellous bone graft in medial open wedge high tibial osteotomy with 2-year follow-up. *Knee Surgery and Related Research* 2013 **25** 117–125. (<https://doi.org/10.5792/ksrr.2013.25.3.117>)
- 31. Ibrahim MS, Raja S & Haddad FS.** Acetabular impaction bone grafting in total hip replacement. *Bone and Joint Journal* 2013 **95-B**(Supplement A) 98–102. (<https://doi.org/10.1302/0301-620X.95B11.32834>)
- 32. Korompilias AV, Lykissas MG, Beris AE, Urbaniak JR & Soucacos PN.** Vascularised fibular graft in the management of femoral head osteonecrosis: twenty years later. *Journal of Bone and Joint Surgery. British Volume* 2009 **91** 287–293. (<https://doi.org/10.1302/0301-620X.91B3.21846>)
- 33. Al-Jabri T, Mannan A & Giannoudis P.** The use of the free vascularised bone graft for nonunion of the scaphoid: a systematic review. *Journal of Orthopaedic Surgery and Research* 2014 **9** 21. (<https://doi.org/10.1186/1749-799X-9-21>)
- 34. Schaeffer CV & Stranix JT.** Tackling bone loss of the lower extremity: vascularized bone grafting. *Plastic and Aesthetic Research* 2022 **9** 27. (<https://doi.org/10.20517/2347-9264.2021.122>)
- 35. Mott A, Mitchell A, McDaid C, Harden M, Gruppig R, Dean A, Byrne A, Doherty L & Sharma H.** Systematic review assessing the evidence for the use of stem cells in fracture healing. *Bone and Joint Open* 2020 **1** 628–638. (<https://doi.org/10.1302/2633-1462.110.BJO-2020-0129>)
- 36. Mazzotta A, Stagni C, Rocchi M, Rani N, Del Piccolo N, Filardo G & Dallari D.** Bone marrow aspirate concentrate/platelet-rich fibrin augmentation accelerates healing of aseptic upper limb nonunions. *Journal of Orthopaedics and Traumatology* 2021 **22** 21. (<https://doi.org/10.1186/s10195-021-00582-y>)
- 37. Schmidt AH.** Autologous bone graft: is it still the gold standard? *Injury* 2021 **52**(Supplement 2) S18–S22. (<https://doi.org/10.1016/j.injury.2021.01.043>)
- 38. Bauer TW & Muschler GF.** Bone graft materials: an overview of the basic science. *Clinical Orthopaedics and Related Research* 2000 (371) 10–27. (<https://doi.org/10.1097/00003086-200002000-00003>)
- 39. Galea G, Kopman D & Graham BJ.** Supply and demand of bone allograft for revision hip surgery in Scotland. *Journal of Bone and Joint Surgery. British Volume* 1998 **80** 595–599. (<https://doi.org/10.1302/0301-620X.80b4.8240>)
- 40. Saha P & Roy S.** Musculoskeletal tissue banking: in orthopaedic perspective. *J Dent med Sci* 2013 **11** 64–68.
- 41. Padley D, Ferguson M, Warwick RM, Womack C, Lucas SB & Saldanha J.** Challenges in the testing of non-heart-beating cadavers for viral markers: implications for the safety of tissue donors. *Cell Tissue Bank* 2005 **6** 171–179. (<https://doi.org/10.1007/s10561-005-5421-9>)
- 42. Mendenhall S.** Bone graft and bone substitutes Orthopaedic. *Network News*.
- 43. Morgan DA, Ilyas I, Bryce SL & Johnson N.** The current state of bone and tissue banking in Australia. *Bulletin* 1998 **57** 39–46.
- 44. Pruss A, Kao M, Gohs U, Koscielny J, von Versen R & Pauli G.** Effect of gamma irradiation on human cortical bone transplants contaminated with enveloped and non-enveloped viruses. *Biologicals: Journal of the International Association of Biological Standardization* 2002 **30** 125–133. (<https://doi.org/10.1006/biol.2002.0326>)
- 45. Cornu O, Banse X, Docquier PL, Luyckx S & Delloye C.** Effect of freeze-drying and gamma irradiation on the mechanical properties of human cancellous bone. *Journal*

of *Orthopaedic Research: Official Publication of the Orthopaedic Research Society* 2000 **18** 426–431. (<https://doi.org/10.1002/jor.1100180314>)

**46. Gruskin E, Doll BA, Futrell FW, Schmitz JP & Hollinger JO.** Demineralized bone matrix in bone repair: history and use. *Advanced Drug Delivery Reviews* 2012 **64** 1063–1077. (<https://doi.org/10.1016/j.addr.2012.06.008>)

**47. Kuchinad RA, Garbedian S, Rogers BA, Backstein D, Safir O & Gross AE.** The use of structural allograft in primary and revision knee arthroplasty with bone loss. *Advances in Orthopedics*. **CL Nelson**, Ed. 2011 **2011** 578952. (<https://doi.org/10.4061/2011/578952>)

**48. Haddad FS, Duncan CP, Berry DJ, Lewallen DG, Gross AE & Chandler HP.** Periprosthetic femoral fractures around well-fixed implants: use of cortical onlay allografts with or without a plate. *Journal of Bone and Joint Surgery. American Volume* 2002 **84** 945–950. (<https://doi.org/10.2106/00004623-200206000-00008>)

**49. Font-Vizcarra L, Fernandez-Valencia JA, Gallart X, Segur JM, Prat S & Riba J.** Cortical strut allograft as an adjunct to plate fixation for periprosthetic fractures of the femur. *Hip International* 2010 **20** 43–49. (<https://doi.org/10.1177/11207000100200s708>)

**50. Wisanuyotin T, Paholpak P, Sirichativapee W & Kosuwon W.** Allograft versus autograft for reconstruction after resection of primary bone tumors: a comparative study of long-term clinical outcomes and risk factors for failure of reconstruction. *Scientific Reports* 2022 **12** 14346. (<https://doi.org/10.1038/s41598-022-18772-x>)

**51. Valdivia Zúñiga CA & De Cicco FL.** Osteochondral allograft. In StatPearls [Internet] Treasure island (FL): StatPearls Publishing 2022.

**52. Torrie AM, Kesler WW, Elkin J & Gallo RA.** Osteochondral allograft. *Current Reviews in Musculoskeletal Medicine* 2015 **8** 413–422. (<https://doi.org/10.1007/s12178-015-9298-3>)

**53. León SA, Mei XY, Safir OA, Gross AE & Kuzyk PR.** Long-term results of fresh osteochondral allografts and realignment osteotomy for cartilage repair in the knee. *Bone and Joint Journal* 2019 **101-B**(1\_Suppl\_A) 46–52. (<https://doi.org/10.1302/0301-620X.101B1.BJJ-2018-0407.R1>)

**54. van der Stok J, Hartholt KA, Schoenmakers DAL & Arts JJC.** The available evidence on demineralised bone matrix in trauma and orthopaedic surgery: a systematic review. *Bone and Joint Research* 2017 **6** 423–432. (<https://doi.org/10.1302/2046-3758.67.BJR-2017-0027.R1>)

**55. Laurencin CT & El-Amin SF.** Xenotransplantation in orthopaedic surgery. *Journal of the American Academy of Orthopaedic Surgeons* 2008 **16** 4–8. (<https://doi.org/10.5435/00124635-200801000-00002>)

**56. Galili U.** Evolution of alpha 1,3galactosyltransferase and of the alpha-Gal epitope. *Subcellular Biochemistry* 1999 **32** 1–23. ([https://doi.org/10.1007/978-1-4615-4771-6\\_1](https://doi.org/10.1007/978-1-4615-4771-6_1))

**57. Amid R, Kheiri A, Kheiri L, Kadhodazadeh M & Ekhlasmankermani M.** Structural and chemical features of xenograft bone substitutes: a systematic review of in vitro studies. *Biotechnology and Applied Biochemistry* 2021 **68** 1432–1452. (<https://doi.org/10.1002/bab.2065>)

**58. Kawecki M, Łabuś W, Klama-Baryła A, Kitala D, Kraut M, Glik J, Misiuga M, Nowak M, Bielecki T & Kasperczyk A.** A review of decellularization methods caused by an urgent need for quality control of cell-free extracellular matrix scaffolds and their role in regenerative medicine. *Journal of Biomedical Materials Research. Part B, Applied Biomaterials* 2018 **106** 909–923. (<https://doi.org/10.1002/jbm.b.33865>)

**59. Charalambides C, Beer M & Cobb AG.** Poor results after augmenting autograft with xenograft (Surgibone) in hip revision surgery: a report of 27 cases. *Acta Orthopaedica* 2005 **76** 544–549. (<https://doi.org/10.1080/17453670510041547>)

**60. Ledford CK, Nunley JA 2nd, Viens NA & Lark RK.** Bovine xenograft failures in pediatric foot reconstructive surgery. *Journal of Pediatric Orthopedics* 2013 **33** 458–463. (<https://doi.org/10.1097/BPO.0b013e318287010d>)

**61. Shibuya N, Jupiter DC, Clawson LD & La Fontaine J.** Incorporation of bovine-based structural bone grafts used in reconstructive foot surgery. *Journal of Foot and Ankle Surgery: Official Publication of the American College of Foot and Ankle Surgeons* 2012 **51** 30–33. (<https://doi.org/10.1053/j.jfas.2011.09.008>)

**62. Xie Y, Chopin D, Hardouin P & Lu J.** Clinical, radiological and histological study of the failure of cervical interbody fusions with bone substitutes. *European Spine Journal* 2006 **15** 1196–1203. (<https://doi.org/10.1007/s00586-005-0052-1>)

**63. Makridis KG, Ahmad MA, Kanakaris NK, Fragkakis EM & Giannoudis PV.** Reconstruction of iliac crest with bovine cancellous allograft after bone graft harvest for symphysis pubis arthrodesis. *International Orthopaedics* 2012 **36** 1701–1707. (<https://doi.org/10.1007/s00264-012-1572-z>)

**64. Bansal MR, Bhagat SB & Shukla DD.** Bovine cancellous xenograft in the treatment of tibial plateau fractures in elderly patients. *International Orthopaedics* 2009 **33** 779–784. (<https://doi.org/10.1007/s00264-008-0526-y>)

**65. Werber KD, Brauer RB, Weiss W & Becker K.** Osseous integration of bovine hydroxyapatite ceramic in metaphyseal bone defects of the distal radius. *Journal of Hand Surgery* 2000 **25** 833–841. (<https://doi.org/10.1053/jhsu.2000.16354>)

**66. Bracey DN, Cignetti NE, Jinnah AH, Stone AV, Gyr BM, Whitlock PW & Scott AT.** Bone xenotransplantation: a review of the history, orthopedic clinical literature, and a single-center case series. *Xenotransplantation* 2020 **27** e12600. (<https://doi.org/10.1111/xen.12600>)

**67. Bragdon B, Moseychuk O, Saldanha S, King D, Julian J & Nohe A.** Bone morphogenetic proteins: a critical review. *Cellular Signalling* 2011 **23** 609–620. (<https://doi.org/10.1016/j.cellsig.2010.10.003>)

**68. Katagiri T & Watabe T.** Bone morphogenetic proteins. *Cold Spring Harbor Perspectives in Biology* 2016 **8**. (<https://doi.org/10.1101/cshperspect.a021899>)

**69. von Einem S, Schwarz E & Rudolph R.** A novel TWO-STEP renaturation procedure for efficient production of recombinant BMP-2. *Protein Expression and Purification* 2010 **73** 65–69. (<https://doi.org/10.1016/j.pep.2010.03.009>)

**70. Friedlaender GE, Perry CR, Cole JD, et al.** Osteogenic protein-1 (bone morphogenetic protein-7) in the treatment of tibial nonunions. *Journal of Bone and Joint Surgery. Am.* 2001;83-A Suppl **2**(Supplement 1) S151–S158.

**71. Wang EA, Rosen V, D'Alessandro JS, Bauduy M, Cordes P, Harada T, Israel DI, Hewick RM, Kerns KM & LaPan P.** Recombinant human bone morphogenetic protein induces bone formation. *Proceedings of the National Academy of Sciences of the United States of America* 1990 **87** 2220–2224. (<https://doi.org/10.1073/pnas.87.6.2220>)

**72. Govender S, Csimma C, Genant HK, Valentin-Opran A, Amit Y, Arbel R, Aro H, Atar D, Bishay M, Börner MG, et al.** Recombinant human bone morphogenetic protein-2 for treatment of open tibial fractures: a prospective, controlled, randomized study of four hundred and fifty patients. *Journal of Bone and Joint Surgery. American Volume* 2002 **84** 2123–2134. (<https://doi.org/10.2106/00004623-200212000-00001>)

**73. Cook SD, Barrack RL, Shimmin A, Morgan D & Carvajal JP.** The use of osteogenic protein-1 in reconstructive surgery of the hip. *Journal of Arthroplasty* 2001 **16**(Supplement 1) 88–94. (<https://doi.org/10.1054/arth.2001.28363>)

**74. Papanagioutou M, Dailiana ZH, Karachalios T, Varitimidis S, Vlychou M, Hantes M & Malizos KN.** RhBMP-7 for the treatment of nonunion of fractures of long

- bones. *Bone and Joint Journal* 2015 **97-B** 997–1003. (<https://doi.org/10.1302/0301-620X.97B7.35089>)
- 75. Kanakaris NK, Lasanianos N, Calori GM, Verdonk R, Blokhuis TJ, Cherubino P, De Biase P & Giannoudis PV.** Application of bone morphogenetic proteins to femoral non-unions: a 4-year multicentre experience. *Injury* 2009 **40**(Supplement 3) S54–S61. ([https://doi.org/10.1016/S0020-1383\(09\)70013-0](https://doi.org/10.1016/S0020-1383(09)70013-0))
- 76. Giannoudis PV, Kanakaris NK, Dimitriou R, Gill I, Kolimarala V & Montgomery RJ.** The synergistic effect of autograft and BMP-7 in the treatment of atrophic nonunions. *Clinical Orthopaedics and Related Research* 2009 **467** 3239–3248. (<https://doi.org/10.1007/s11999-009-0846-2>)
- 77. Salkeld SL, Patron LP, Barrack RL & Cook SD.** The effect of osteogenic protein-1 on the healing of segmental bone defects treated with autograft or allograft bone. *Journal of Bone and Joint Surgery. American Volume* 2001 **83** 803–816. (<https://doi.org/10.2106/00004623-200106000-00001>)
- 78. Haubruck P, Tanner MC, Vlachopoulos W, Hagelskamp S, Miska M, Ober J, Fischer C & Schmidmaier G.** Comparison of the clinical effectiveness of bone morphogenetic protein (BMP) -2 and -7 in the adjunct treatment of lower limb nonunions. *Orthopaedics and Traumatology, Surgery and Research* 2018 **104** 1241–1248. (<https://doi.org/10.1016/j.otsr.2018.08.008>)
- 79. Conway JD, Shabtai L, Bauernschub A & Specht SC.** BMP-7 versus BMP-2 for the treatment of long bone nonunion. *Orthopedics* 2014 **37** e1049–e1057. (<https://doi.org/10.3928/01477447-20141124-50>)
- 80. Cahill KS, Chi JH, Day A & Claus EB.** Prevalence, complications, and hospital charges associated with use of bone-morphogenetic proteins in spinal fusion procedures. *JAMA* 2009 **302** 58–66. (<https://doi.org/10.1001/jama.2009.956>)
- 81. Boraiah S, Paul O, Hawkes D, Wickham M & Lorich DG.** Complications of recombinant human BMP-2 for treating complex tibial plateau fractures: a preliminary report. *Clinical Orthopaedics and Related Research* 2009 **467** 3257–3262. (<https://doi.org/10.1007/s11999-009-1039-8>)
- 82. Simpson AHRW, Mills L & Noble B.** The role of growth factors and related agents in accelerating fracture healing. *Journal of Bone and Joint Surgery. British Volume* 2006 **88** 701–705. (<https://doi.org/10.1302/0301-620X.88B6.17524>)
- 83. Veillette CJH & McKee MD.** Growth factors—BMPs, DBMs, and buffy coat products: are there any proven differences amongst them? *Injury* 2007 **38**(Supplement 1) S38–S48. (<https://doi.org/10.1016/j.injury.2007.02.009>)
- 84. Kanno T, Takahashi T, Tsujisawa T, Ariyoshi W & Nishihara T.** Platelet-rich plasma enhances human osteoblast-like cell proliferation and differentiation. *Journal of Oral and Maxillofacial Surgery: Official Journal of the American Association of Oral and Maxillofacial Surgeons* 2005 **63** 362–369. (<https://doi.org/10.1016/j.joms.2004.07.016>)
- 85. Dhurat R & Sukesh M.** Principles and methods of preparation of platelet-rich plasma: a review and author's perspective. *Journal of Cutaneous and Aesthetic Surgery* 2014 **7** 189–197. (<https://doi.org/10.4103/0974-2077.150734>)
- 86. Rughetti A, Giusti I, D'Ascenzo S, Leocata P, Carta G, Pavan A, Dell'Orso L & Dolo V.** Platelet gel-released supernatant modulates the angiogenic capability of human endothelial cells. *Blood Transfusion* 2008 **6** 12–17. (<https://doi.org/10.2450/2008.0026-07>)
- 87. Zhang Y, Xing F, Luo R & Duan X.** Platelet-rich plasma for bone fracture treatment: a systematic review of current evidence in preclinical and clinical studies. *Frontiers in Medicine* 2021 **8** 676033. (<https://doi.org/10.3389/fmed.2021.676033>)
- 88. Griffin XL, Smith CM & Costa ML.** The clinical use of platelet-rich plasma in the promotion of bone healing: a systematic review. *Injury* 2009 **40** 158–162. (<https://doi.org/10.1016/j.injury.2008.06.025>)
- 89. Acosta-Olivo C, Garza-Borjon A, Simental-Mendia M, Vilchez-Cavazos F, Tamez-Mata Y & Peña-Martinez V.** Delayed union of humeral shaft fractures: comparison of autograft with and without platelet-rich plasma treatment: a randomized, single blinded clinical trial. *Archives of Orthopaedic and Trauma Surgery* 2017 **137** 1247–1252. (<https://doi.org/10.1007/s00402-017-2736-5>)
- 90. Chiang CC, Su CY, Huang CK, Chen WM, Chen TH & Tzeng YH.** Early experience and results of bone graft enriched with autologous platelet gel for recalcitrant nonunions of lower extremity. *Journal of Trauma* 2007 **63** 655–661. (<https://doi.org/10.1097/01.ta.0000219937.51190.37>)
- 91. Tarallo L, Mugnai R, Adani R & Catani F.** Treatment of the ulna non-unions using dynamic compression plate fixation, iliac bone grafting and autologous platelet concentrate. *European Journal of Orthopaedic Surgery and Traumatology: Orthopedie Traumatologie* 2012 **22** 681–687. (<https://doi.org/10.1007/s00590-011-0902-y>)
- 92. Ghaffarpasand F, Shahrezaei M & Dehghankhalili M.** Effects of platelet rich plasma on healing rate of long bone non-union fractures: a randomized double-blind placebo controlled clinical trial. *Bulletin of Emergency and Trauma* 2016 **4** 134–140.
- 93. Samuel G, Menon J, Thimmaiah S & Behera G.** Role of isolated percutaneous autologous platelet concentrate in delayed union of long bones. *European Journal of Orthopaedic Surgery and Traumatology: Orthopedie Traumatologie* 2018 **28** 985–990. (<https://doi.org/10.1007/s00590-017-2077-7>)
- 94. Duramaz A, Ursavaş HT, Bilgili MG, Bayrak A, Bayram B & Avkan MC.** Platelet-rich plasma versus exchange intramedullary nailing in treatment of long bone oligotrophic nonunions. *European Journal of Orthopaedic Surgery and Traumatology: Orthopedie Traumatologie* 2018 **28** 131–137. (<https://doi.org/10.1007/s00590-017-2024-7>)
- 95. Bielecki T, Gazdzik TS & Szczepanski T.** Benefit of percutaneous injection of autologous platelet-leukocyte-rich gel in patients with delayed union and nonunion. *European Surgical Research. Europäische Chirurgische Forschung. Recherches Chirurgicales Européennes* 2008 **40** 289–296. (<https://doi.org/10.1159/000114967>)
- 96. Malhotra R, Kumar V, Garg B, Singh R, Jain V, Coshic P & Chatterjee K.** Role of autologous platelet-rich plasma in treatment of long-bone nonunions: a prospective study. *Musculoskeletal Surgery* 2015 **99** 243–248. (<https://doi.org/10.1007/s12306-015-0378-8>)
- 97. Pountos I, Panteli M, Lampropoulos A, Jones E, Calori GM & Giannoudis PV.** The role of peptides in bone healing and regeneration: a systematic review. *BMC Medicine* 2016 **14** 103. (<https://doi.org/10.1186/s12916-016-0646-y>)
- 98. Whitfield JF, Morley P & Willick GE.** Parathyroid hormone, its fragments and their analogs for the treatment of osteoporosis. *Treatments in Endocrinology* 2002 **1** 175–190. (<https://doi.org/10.2165/00024677-200201030-00005>)
- 99. Oteo-Alvaro A & Moreno E.** Atrophic humeral shaft nonunion treated with teriparatide (rh PTH 1–34): a case report. *Journal of Shoulder and Elbow Surgery* 2010 **19** e22–e28. (<https://doi.org/10.1016/j.jse.2010.05.005>)
- 100. Paridis D & Karachalios T.** Atrophic femoral bone nonunion treated with 1–84 PTH. *Journal of Musculoskeletal and Neuronal Interactions* 2011 **11** 320–323.
- 101. Pietrogrande L & Raimondo E.** Teriparatide in the treatment of non-unions: scientific and clinical evidences. *Injury* 2013 **44**(Supplement 1) S54–S57. ([https://doi.org/10.1016/S0020-1383\(13\)70013-5](https://doi.org/10.1016/S0020-1383(13)70013-5))

- 102. Yu CT, Wu JK, Chang CC, Chen CL & Wei JC-C.** Early callus formation in human hip fracture treated with internal fixation and teriparatide. *Journal of Rheumatology* 2008 **35** 2082–2083.
- 103. Fukuda F, Kurinomaru N & Hijioka A.** Weekly teriparatide for delayed unions of atypical subtrochanteric femur fractures. *Biologics in Therapy* 2014 **4** 73–79. (<https://doi.org/10.1007/s13554-014-0013-5>)
- 104. Ochi K, Ikari K, Naomi A & Momohara S.** Administration of teriparatide treatment for a challenging case of nonunion of periprosthetic fracture after total knee arthroplasty. *Archives of Osteoporosis* 2013 **8** 159. (<https://doi.org/10.1007/s11657-013-0159-7>)
- 105. Wu CC, Wei JC-C, Hsieh CP & Yu CT.** Enhanced healing of sacral and pubic insufficiency fractures by teriparatide. *Journal of Rheumatology* 2012 **39** 1306–1307. (<https://doi.org/10.3899/jrheum.111458>)
- 106. Wang YH, Qiu Y, Han XD, Xiong J, Chen YX, Shi HF & Karaplis A.** Haploinsufficiency of endogenous parathyroid hormone-related peptide impairs bone fracture healing. *Clinical and Experimental Pharmacology and Physiology* 2013 **40** 715–723. (<https://doi.org/10.1111/1440-1681.12161>)
- 107. Du P, Ye Y, Seitz PK, Bi LG, Li H, Wang C, Simmons DJ & Cooper CW.** Endogenous parathyroid hormone-related peptide enhances proliferation and inhibits differentiation in the osteoblast-like cell line ROS 17/2.8. *Bone* 2000 **26** 429–436. ([https://doi.org/10.1016/S8756-3282\(00\)00264-7](https://doi.org/10.1016/S8756-3282(00)00264-7))
- 108. Cupp ME, Nayak SK, Adem AS & Thomsen WJ.** Parathyroid hormone (PTH) and PTH-related peptide domains contributing to activation of different PTH receptor-mediated signaling pathways. *Journal of Pharmacology and Experimental Therapeutics* 2013 **345** 404–418. (<https://doi.org/10.1124/jpet.112.199752>)
- 109. Wang Y, Fang X, Wang C, Ding C, Lin H, Liu A, Wang L & Cao Y.** Exogenous PTHrP repairs the damaged fracture healing of PTHrP+/- mice and accelerates fracture healing of wild mice. *International Journal of Molecular Sciences* 2017 **18**. (<https://doi.org/10.3390/ijms18020337>)
- 110. Bostrom MP, Gamradt SC, Asnis P, Vickery BH, Hill E, Avnur Z & Waters RV.** Parathyroid hormone-related protein analog RS-66271 is an effective therapy for impaired bone healing in rabbits on corticosteroid therapy. *Bone* 2000 **26** 437–442. ([https://doi.org/10.1016/S8756-3282\(00\)00251-9](https://doi.org/10.1016/S8756-3282(00)00251-9))
- 111. Miller PD, Hattersley G, Riis BJ, Williams GC, Lau E, Russo LA, Alexandersen P, Zerbin CA, Hu MY, Harris AG, et al.** Effect of abaloparatide vs placebo on new vertebral fractures in postmenopausal women with osteoporosis: a randomized clinical trial. *JAMA* 2016 **316** 722–733. (<https://doi.org/10.1001/jama.2016.11136>)
- 112. Kruger L, Silverman JD, Mantyh PW, Sternini C & Brecha NC.** Peripheral patterns of calcitonin-related peptide general somatic sensory innervation: cutaneous and deep terminations. *Journal of Comparative Neurology* 1989 **280** 291–302. (<https://doi.org/10.1002/cne.902800210>)
- 113. Onuoha GN.** Circulating sensory peptide levels within 24 h of human bone fracture. *Peptides* 2001 **22** 1107–1110. ([https://doi.org/10.1016/S0196-9781\(01\)00434-x](https://doi.org/10.1016/S0196-9781(01)00434-x))
- 114. Ballica R, Valentijn K, Khachatryan A, Guerder S, Kapadia S, Gundberg C, Gilligan J, Flavell RA & Vignery A.** Targeted expression of calcitonin gene-related peptide to osteoblasts increases bone density in mice. *Journal of Bone and Mineral Research* 1999 **14** 1067–1074. (<https://doi.org/10.1359/jbmr.1999.14.7.1067>)
- 115. Madsen JE, Hukkanen M, Aune AK, Basran I, Møller JF, Polak JM & Nordsletten L.** Fracture healing and callus innervation after peripheral nerve resection in rats. *Clinical Orthopaedics and Related Research* 1998 **351** 230–240. (<https://doi.org/10.1097/00003086-199806000-00028>)
- 116. An G, Xue Z, Zhang B, Deng QK, Wang YS & Lv SC.** Expressing osteogenic growth peptide in the rabbit bone mesenchymal stem cells increased alkaline phosphatase activity and enhanced the collagen accumulation. *European Review for Medical and Pharmacological Sciences* 2014 **18** 1618–1624.
- 117. Fei Q, Guo C, Xu X, Gao J, Zhang J, Chen T & Cui D.** Osteogenic growth peptide enhances the proliferation of bone marrow mesenchymal stem cells from osteoprotegerin-deficient mice by CDK2/cyclin A. *Acta Biochimica et Biophysica Sinica* 2010 **42** 801–806. (<https://doi.org/10.1093/abbs/gmq086>)
- 118. Spreafico A, Frediani B, Capperucci C, Leonini A, Gambera D, Ferrata P, Rosini S, Di Stefano A, Galeazzi M & Marcolongo R.** Osteogenic growth peptide effects on primary human osteoblast cultures: potential relevance for the treatment of glucocorticoid-induced osteoporosis. *Journal of Cellular Biochemistry* 2006 **98** 1007–1020. (<https://doi.org/10.1002/jcb.20836>)
- 119. Sun YQ & Ashhurst DE.** Osteogenic growth peptide enhances the rate of fracture healing in rabbits. *Cell Biology International* 1998 **22** 313–319. (<https://doi.org/10.1006/cbir.1998.0253>)
- 120. Shuqiang M, Kunzheng W, Xiaoqiang D, Wei W, Mingyu Z & Daocheng W.** Osteogenic growth peptide incorporated into PLGA scaffolds accelerates healing of segmental long bone defects in rabbits. *Journal of Plastic, Reconstructive and Aesthetic Surgery* 2008 **61** 1558–1560. (<https://doi.org/10.1016/j.bjps.2008.03.040>)
- 121. Fernandez de Grado G, Keller L, Idoux-Gillet Y, Wagner Q, Musset AM, Benkirane-Jessel N, Bornert F & Offner D.** Bone substitutes: a review of their characteristics, clinical use, and perspectives for large bone defects management. *Journal of Tissue Engineering* 2018 **9** 2041731418776819. (<https://doi.org/10.1177/2041731418776819>)
- 122. Bohner M, Santoni BLG & Döbelin N.**  $\beta$ -tricalcium phosphate for bone substitution: synthesis and properties. *Acta Biomaterialia* 2020 **113** 23–41. (<https://doi.org/10.1016/j.actbio.2020.06.022>)
- 123. Famery R, Richard N & Boch P.** Preparation of  $\alpha$ - and  $\beta$ -tricalcium phosphate ceramics, with and without magnesium addition. *Ceramics International* 1994 **20** 327–336. ([https://doi.org/10.1016/0272-8842\(94\)90050-7](https://doi.org/10.1016/0272-8842(94)90050-7))
- 124. Kanazawa T, Umegaki T & Uchiyama N.** Thermal crystallisation of amorphous calcium phosphate to  $\alpha$ -tricalcium phosphate. *Journal of Chemical Technology and Biotechnology* 1982 **32** 399–406. (<https://doi.org/10.1002/jctb.5030320206>)
- 125. Stähli C, Thüring J, Galea L, Tadier S, Bohner M & Döbelin N.** Hydrogen-substituted  $\beta$ -tricalcium phosphate synthesized in organic media. *Acta Crystallographica Section B, Structural Science, Crystal Engineering and Materials* 2016 **72** 875–884. (<https://doi.org/10.1107/S2052520616015675>)
- 126. Rolvien T, Barvenčík F, Klatté TO, Busse B, Hahn M, Rueger JM & Ruppert M.**  $\beta$ -TCP bone substitutes in tibial plateau depression fractures. *Knee* 2017 **24** 1138–1145. (<https://doi.org/10.1016/j.knee.2017.06.010>)
- 127. Galois L, Mainard D & Delagoutte JP.** Beta-tricalcium phosphate ceramic as a bone substitute in orthopaedic surgery. *International Orthopaedics* 2002 **26** 109–115. (<https://doi.org/10.1007/s00264-001-0329-x>)
- 128. Jakubietz MG, Gruenert JG & Jakubietz RG.** The use of beta-tricalcium phosphate bone graft substitute in dorsally plated, comminuted distal radius fractures. *Journal of Orthopaedic Surgery and Research* 2011 **6** 24. (<https://doi.org/10.1186/1749-799X-6-24>)
- 129. Shen C, Ma J, Chen XD & Dai LY.** The use of beta-TCP in the surgical treatment of tibial plateau fractures. *Knee Surgery, Sports Traumatology, Arthroscopy* 2009 **17** 1406–1411. (<https://doi.org/10.1007/s00167-009-0726-z>)



- 130. Hernigou P, Dubory A, Pariat J, Potage D, Roubineau F, Jammal S & Flouzat Lachaniette CH.** Beta-tricalcium phosphate for orthopedic reconstructions as an alternative to autogenous bone graft. *Morphologie: Bulletin de l'Association des Anatomistes* 2017 **101** 173–179. (<https://doi.org/10.1016/j.morpho.2017.03.005>)
- 131. Orsini G, Ricci J, Scarano A, Pecora G, Petrone G, Iezzi G & Piattelli A.** Bone-defect healing with calcium-sulfate particles and cement: an experimental study in rabbit. *Journal of Biomedical Materials Research. Part B, Applied Biomaterials* 2004 **68** 199–208. (<https://doi.org/10.1002/jbm.b.20012>)
- 132. Ene R, Nica M, Ene D, Cursaru A & Cirstoiu C.** Review of calcium-sulphate-based ceramics and synthetic bone substitutes used for antibiotic delivery in PJI and osteomyelitis treatment. *EFORT Open Reviews* 2021 **6** 297–304. (<https://doi.org/10.1302/2058-5241.6.200083>)
- 133. Wichelhaus TA, Dingeldein E, Rauschmann M, Kluge S, Dieterich R, Schäfer V & Brade V.** Elution characteristics of vancomycin, teicoplanin, gentamicin and clindamycin from calcium sulphate beads. *Journal of Antimicrobial Chemotherapy* 2001 **48** 117–119. (<https://doi.org/10.1093/jac/48.1.117>)
- 134. McNally MA, Ferguson JY, Scarborough M, Ramsden A, Stubbs DA & Atkins BL.** Mid- to long-term results of single-stage surgery for patients with chronic osteomyelitis using a bioabsorbable gentamicin-loaded ceramic carrier. *Bone and Joint Journal* 2022 **104-B** 1095–1100. (<https://doi.org/10.1302/0301-620X.104B9.BJJ-2022-0396.R1>)
- 135. Rodham P, Panteli M, Qin C, Harwood P & Giannoudis PV.** Long-term outcomes of lower limb post-traumatic osteomyelitis. *European Journal of Trauma and Emergency Surgery* 2023 **49** 539–549. (<https://doi.org/10.1007/s00068-022-02104-9>)
- 136. Rodham P, Panteli M, Vun JSH, Harwood P & Giannoudis PV.** Lower limb post-traumatic osteomyelitis: a systematic review of clinical outcomes. *European Journal of Orthopaedic Surgery and Traumatology: Orthopedie Traumatologie* 2022. (<https://doi.org/10.1007/s00590-022-03364-2>)
- 137. Kumar CY, K B N, Menon J, Patro DK & B H B.** Calcium sulfate as bone graft substitute in the treatment of osseous bone defects, a prospective study. *Journal of Clinical and Diagnostic Research* 2013 **7** 2926–2928. (<https://doi.org/10.7860/JCDR/2013/6404.3791>)
- 138. Kelly CM, Wilkins RM, Gitelis S, Hartjen C, Watson JT & Kim PT.** The use of a surgical grade calcium sulfate as a bone graft substitute: results of a multicenter trial. *Clinical Orthopaedics and Related Research* 2001 **382** 42–50. (<https://doi.org/10.1097/00003086-200101000-00008>)
- 139. Sohn HS & Oh JK.** Review of bone graft and bone substitutes with an emphasis on fracture surgeries. *Biomaterials Research* 2019 **23** 9. (<https://doi.org/10.1186/s40824-019-0157-y>)
- 140. Kattimani VS, Kondaka S & Lingamaneni KP.** Hydroxyapatite—past, present, and future in bone regeneration. *Bone and Tissue Regeneration Insights* 2016 **7** BTRI.S36138. (<https://doi.org/10.4137/BTRI.S36138>)
- 141. Fujita R, Yokoyama A, Kawasaki T & Kohgo T.** Bone augmentation osteogenesis using hydroxyapatite and beta-tricalcium phosphate blocks. *Journal of Oral and Maxillofacial Surgery: Official Journal of the American Association of Oral and Maxillofacial Surgeons* 2003 **61** 1045–1053. ([https://doi.org/10.1016/s0278-2391\(03\)00317-3](https://doi.org/10.1016/s0278-2391(03)00317-3))
- 142. den Boer FC, Wippermann BW, Blokhuis TJ, Patka P, Bakker FC & Haarman HJTM.** Healing of segmental bone defects with granular porous hydroxyapatite augmented with recombinant human osteogenic protein-1 or autologous bone marrow. *Journal of Orthopaedic Research* 2003 **21** 521–528. ([https://doi.org/10.1016/S0736-0266\(02\)00205-X](https://doi.org/10.1016/S0736-0266(02)00205-X))
- 143. Søballe K, Hansen ES, B-Rasmussen H, Jørgensen PH & Bünger C.** Tissue ingrowth into titanium and hydroxyapatite-coated implants during stable and unstable mechanical conditions. *Journal of Orthopaedic Research* 1992 **10** 285–299. (<https://doi.org/10.1002/jor.1100100216>)
- 144. Pizà G, Caja VL, González-Viejo MA & Navarro A.** Hydroxyapatite-coated external-fixation pins. The effect on pin loosening and pin-track infection in leg lengthening for short stature. *Journal of Bone and Joint Surgery. British Volume* 2004 **86** 892–897. (<https://doi.org/10.1302/0301-620X.86b6.13875>)
- 145. Madison J, Oliver JN & Zhu D.** Bioactive glasses in orthopedic applications BT - racing for the surface: antimicrobial and interface tissue engineering. In B Li, TF Moriarty, T Webster & M Xing, Eds. Springer International Publishing 2020, pp. 557–575. ([https://doi.org/10.1007/978-3-030-34471-9\\_21](https://doi.org/10.1007/978-3-030-34471-9_21))
- 146. Tilocca A.** Structure and dynamics of bioactive phosphosilicate glasses and melts from ab initio molecular dynamics simulations. *Physical Review. Part B* 2007 **76** 224202. (<https://doi.org/10.1103/PhysRevB.76.224202>)
- 147. Jacobson RE, Granville M, Hatgis J & Berti A.** Low volume vertebral augmentation with Cortoss® cement for treatment of high degree vertebral compression fractures and vertebra plana. *Cureus* 2017 **9** e1058. (<https://doi.org/10.7759/cureus.1058>)
- 148. Aurégan JC & Bégué T.** Bioactive glass for long bone infection: a systematic review. *Injury* 2015 **46**(Supplement 8) S3–S7. ([https://doi.org/10.1016/S0020-1383\(15\)30048-6](https://doi.org/10.1016/S0020-1383(15)30048-6))
- 149. Ziegenhain F, Neuhaus V & Pape H-C.** Bioactive glass in the treatment of chronic osteomyelitis—a valid option? *OTA International* 2021 **4** 35. (<https://doi.org/10.1097/O19.000000000000105>)
- 150. Van Vugt TAG, Geurts JAP & Blokhuis TJ.** Treatment of infected tibial non-unions using a BMAC and S53P4 BAG combination for reconstruction of segmental bone defects: a clinical case series. *Injury* 2021 **52**(Supplement 2) S67–S71. (<https://doi.org/10.1016/j.injury.2020.09.029>)
- 151. Aurégan JC, Villain B, Glombitza M, Blokhuis T, Heinänen M & Bégué T.** Utilisation of bioactive glass S53P4 inside an induced membrane for severe bone defect with high risk of infection: a multi-center preliminary experience. *Injury* 2022 **53**(Supplement 2) S13–S19. (<https://doi.org/10.1016/j.injury.2022.07.027>)
- 152. Pernaà K, Koski I, Mattila K, Gullichsen E, Heikkilä J, Aho A & Lindfors N.** Bioactive glass S53P4 and autograft bone in treatment of depressed tibial plateau fractures – a prospective randomized 11-year follow-up. *Journal of Long-Term Effects of Medical Implants* 2011 **21** 139–148. (<https://doi.org/10.1615/jlongtermeffmedimplants.v21.i2.40>)
- 153. Heikkilä JT, Kukkonen J, Aho AJ, Moisander S, Kyrrönen T & Mattila K.** Bioactive glass granules: a suitable bone substitute material in the operative treatment of depressed lateral tibial plateau fractures: a prospective, randomized 1 year follow-up study. *Journal of Materials Science. Materials in Medicine* 2011 **22** 1073–1080. (<https://doi.org/10.1007/s10856-011-4272-0>)
- 154. Kaur G, Kumar V, Bains F, Mauro JC, Pickrell G, Evans I & Bretcanu O.** Mechanical properties of bioactive glasses, ceramics, glass-ceramics and composites: state-of-the-art review and future challenges. *Materials Science and Engineering. C, Materials for Biological Applications* 2019 **104** 109895. (<https://doi.org/10.1016/j.msec.2019.109895>)
- 155. Ferreira J & Rebelo A.** The key features expected from a perfect bioactive glass “How far are we from an ideal composition.” *Biomedical Journal of Scientific & Technical Research* 2017 **1** 936–939. (<https://doi.org/10.26717/BJSTR.2017.01.000335>)

- 156. Holmes R, Mooney V, Bucholz R & Tencer A.** A coralline hydroxyapatite bone graft substitute. Preliminary report. *Clinical Orthopaedics and Related Research* 1984 **188** 252–262. (<https://doi.org/10.1097/0003086-198409000-00036>)
- 157. Ripamonti U.** The morphogenesis of bone in replicas of porous hydroxyapatite obtained from conversion of calcium carbonate exoskeletons of coral. *Journal of Bone and Joint Surgery. American Volume* 1991 **73** 692–703. (<https://doi.org/10.2106/00004623-199173050-00007>)
- 158. Guillemin G, Meunier A, Dallant P, Christel P, Pouliquen JC & Sedel L.** Comparison of coral resorption and bone apposition with two natural corals of different porosities. *Journal of Biomedical Materials Research* 1989 **23** 765–779. (<https://doi.org/10.1002/jbm.820230708>)
- 159. Pountos I & Giannoudis PV.** Is there a role of coral bone substitutes in bone repair? *Injury* 2016 **47** 2606–2613. (<https://doi.org/10.1016/j.injury.2016.10.025>)
- 160. Tran CT, Gargiulo C, Thao HD, Tuan HM, Filgueira L & Michael Strong D.** Culture and differentiation of osteoblasts on coral scaffold from human bone marrow mesenchymal stem cells. *Cell Tissue Bank* 2011 **12** 247–261. (<https://doi.org/10.1007/s10561-010-9208-2>)
- 161. Sautier JM, Nefussi JR, Boulekbache H & Forest N.** In vitro bone formation on coral granules. *In Vitro Cellular and Developmental Biology* 1990 **26** 1079–1085. (<https://doi.org/10.1007/BF02624444>)
- 162. Devecioglu D, Tözüm TF, Sengün D & Nohutcu RM.** Biomaterials in periodontal regenerative surgery: effects of cryopreserved bone, commercially available coral, demineralized freeze-dried dentin, and cementum on periodontal ligament fibroblasts and osteoblasts. *Journal of Biomaterials Applications* 2004 **19** 107–120. (<https://doi.org/10.1177/0885328204043818>)
- 163. Al-Salihi KA & Samsudin AR.** Bone marrow mesenchymal stem cells differentiation and proliferation on the surface of coral implant. *Medical Journal of Malaysia* 2004 **59**(Supplement B) 45–46.
- 164. Foo LH, Suzina AH, Azlina A & Kannan TP.** Gene expression analysis of osteoblasts seeded in coral scaffold. *Journal of Biomedical Materials Research. Part A* 2008 **87** 215–221. (<https://doi.org/10.1002/jbm.a.31765>)
- 165. Puvanewary S, Balaji Raghavendran HR, Ibrahim NS, Murali MR, Merican AM & Kamarul T.** A comparative study on morphochemical properties and osteogenic cell differentiation within bone graft and coral graft culture systems. *International Journal of Medical Sciences* 2013 **10** 1608–1614. (<https://doi.org/10.7150/ijms.6496>)
- 166. Kim CS, Choi SH, Cho KS, Chai JK, Wikesjö UME & Kim CK.** Periodontal healing in one-wall intra-bony defects in dogs following implantation of autogenous bone or a coral-derived biomaterial. *Journal of Clinical Periodontology* 2005 **32** 583–589. (<https://doi.org/10.1111/j.1600-051X.2005.00729.x>)
- 167. Holmes RE, Bucholz RW & Mooney V.** Porous hydroxyapatite as a bone-graft substitute in metaphyseal defects. A histometric study. *Journal of Bone and Joint Surgery. American Volume* 1986 **68** 904–911. (<https://doi.org/10.2106/00004623-198668060-00013>)
- 168. Coughlin MJ, Grimes JS & Kennedy MP.** Coralline hydroxyapatite bone graft substitute in hindfoot surgery. *Foot and Ankle International* 2006 **27** 19–22. (<https://doi.org/10.1177/107110070602700104>)
- 169. Bucholz RW, Carlton A & Holmes R.** Interporous hydroxyapatite as a bone graft substitute in tibial plateau fractures. *Clinical Orthopaedics and Related Research* 1989 **240** 53–62. (<https://doi.org/10.1097/0003086-198903000-00008>)
- 170. Giannoudis PV, Einhorn TA & Marsh D.** Fracture healing: a harmony of optimal biology and optimal fixation? *Injury* 2007 **38**(Supplement 4) S1–S2. ([https://doi.org/10.1016/s0020-1383\(08\)70002-0](https://doi.org/10.1016/s0020-1383(08)70002-0))
- 171. Giannoudis PV & Kontakis G.** Treatment of long bone aseptic non-unions: monotherapy or polytherapy? *Injury* 2009 **40** 1021–1022. (<https://doi.org/10.1016/j.injury.2009.07.064>)
- 172. Giannoudis PV, Gudipati S, Harwood P & Kanakaris NK.** Long bone non-unions treated with the diamond concept: a case series of 64 patients. *Injury* 2015 **46**(Supplement 8) S48–S54. ([https://doi.org/10.1016/S0020-1383\(15\)30055-3](https://doi.org/10.1016/S0020-1383(15)30055-3))
- 173. Einhorn TA.** The cell and molecular biology of fracture healing. *Clinical Orthopaedics and Related Research* 1998 57–21. (<https://doi.org/10.1097/0003086-199810001-00003>)
- 174. Prendergast PJ & Huiskes R.** The Biomechanics of Wolff's law: recent advances. *Irish Journal of Medical Science* 1995 **164** 152–154. (<https://doi.org/10.1007/BF02973285>)
- 175. Dimitriou R, Jones E, McGonagle D & Giannoudis PV.** Bone regeneration: current concepts and future directions. *BMC Medicine* 2011 **9** 66. (<https://doi.org/10.1186/1741-7015-9-66>)
- 176. Perren SM.** Physical and biological aspects of fracture healing with special reference to internal fixation. *Clinical Orthopaedics and Related Research* 1979 **138** 175–196.
- 177. Elliott DS, Newman KJH, Forward DP, Hahn DM, Ollivere B, Kojima K, Handley R, Rossiter ND, Wixted JJ, Smith RM, et al.** A unified theory of bone healing and nonunion: BHN theory. *Bone and Joint Journal* 2016 **98-B** 884–891. (<https://doi.org/10.1302/0301-620X.98B7.36061>)
- 178. Vaughn J, Gotha H, Cohen E, Fantry AJ, Feller RJ, Van Meter J, Hayda R & Born CT.** Nail dynamization for delayed union and nonunion in femur and tibia fractures. *Orthopedics* 2016 **39** e1117–e1123. (<https://doi.org/10.3928/01477447-20160819-01>)
- 179. Kothari A, Monk P & Handley R.** Percutaneous strain reduction screws—A safe and simple surgical option for problems with bony union. A technical trick. *Journal of Orthopaedic Trauma* 2019 **33** e151–e157. (<https://doi.org/10.1097/BOT.0000000000001396>)
- 180. Sahu RL & Ranjan R.** Treatment of complex nonunion of the shaft of the tibia using Ilizarov technique and its functional outcome. *Nigerian Medical Journal* 2016 **57** 129–133. (<https://doi.org/10.4103/0300-1652.182076>)
- 181. Hierholzer C, Glowalla C, Herrler M, von Rüden C, Hungerer S, Bühren V & Friederichs J.** Reamed intramedullary exchange nailing: treatment of choice of aseptic femoral shaft nonunion. *Journal of Orthopaedic Surgery and Research* 2014 **9** 88. (<https://doi.org/10.1186/s13018-014-0088-1>)
- 182. Westhauser F, Zimmermann G, Moghaddam S, Bruckner T, Schmidmaier G, Biglari B & Moghaddam A.** Reaming in treatment of non-unions in long bones: cytokine expression course as a tool for evaluation of non-union therapy. *Archives of Orthopaedic and Trauma Surgery* 2015 **135** 1107–1116. (<https://doi.org/10.1007/s00402-015-2253-3>)
- 183. Schofer MD, Block JE, Aigner J & Schmelz A.** Improved healing response in delayed unions of the tibia with low-intensity pulsed ultrasound: results of a randomized sham-controlled trial. *BMC Musculoskeletal Disorders* 2010 **11** 229. (<https://doi.org/10.1186/1471-2474-11-229>)
- 184. Busse JW, Bhandari M, Kulkarni AV & Tunks E.** The effect of low-intensity pulsed ultrasound therapy on time to fracture healing: a meta-analysis. *C Can Med Assoc J = J l'Association medicale Can* 2002 **166** 437–441.
- 185. Leighton R, Watson JT, Giannoudis P, Papakostidis C, Harrison A & Steen RG.** Healing of fracture nonunions treated with low-intensity pulsed ultrasound (LIPUS): a systematic review and meta-analysis. *Injury* 2017 **48** 1339–1347. (<https://doi.org/10.1016/j.injury.2017.05.016>)

- 186. Flierl MA, Smith WR, Mauffrey C, Irgit K, Williams AE, Ross E, Peacher G, Hak DJ & Stahel PF.** Outcomes and complication rates of different bone grafting modalities in long bone fracture nonunions: a retrospective cohort study in 182 patients. *Journal of Orthopaedic Surgery and Research* 2013 **8** 33. (<https://doi.org/10.1186/1749-799X-8-33>)
- 187. Roddy E, DeBaun MR, Daoud-Gray A, Yang YP & Gardner MJ.** Treatment of critical-sized bone defects: clinical and tissue engineering perspectives. *European Journal of Orthopaedic Surgery and Traumatology: Orthopedie Traumatologie* 2018 **28** 351–362. (<https://doi.org/10.1007/s00590-017-2063-0>)
- 188. Chloros GD, Kanakaris NK, Harwood PJ & Giannoudis PV.** Induced membrane technique for acute bone loss and nonunion management of the tibia. *OTA International* 2022 **5**(Supplement) e170. (<https://doi.org/10.1097/OI9.000000000000170>)
- 189. Dimitriou R, Mataliotakis GI, Angoules AG, Kanakaris NK & Giannoudis PV.** Complications following autologous bone graft harvesting from the iliac crest and using the RIA: a systematic review. *Injury* 2011 **42**(Supplement 2) S3–S15. (<https://doi.org/10.1016/j.injury.2011.06.015>)
- 190. Paley D.** Bone transport: the Ilizarov treatment for bone defects. *Techniques in Orthopaedics* 1989 **4** 80–93. (<https://doi.org/10.1097/00013611-198910000-00013>)
- 191. Huang Q, Ma T, Ren C, Xu Y, Li M, Wang Q, Lu Y, Li Z & Zhang K.** Shortening and re-lengthening versus bone transport for the treatment of distal tibial periarticular post-traumatic defects. *Scientific Reports* 2022 **12** 16303. (<https://doi.org/10.1038/s41598-022-20760-0>)
- 192. Aktuglu K, Erol K & Vahabi A.** Ilizarov bone transport and treatment of critical-sized tibial bone defects: a narrative review. *Journal of Orthopaedics and Traumatology* 2019 **20** 22. (<https://doi.org/10.1186/s10195-019-0527-1>)
- 193. Rosteius T, Pätzholz S, Rausch V, Lotzien S, Behr B, Lehnhardt M, Schildhauer TA, Seybold D & Geßmann J.** Ilizarov bone transport using an intramedullary cable transportation system in the treatment of tibial bone defects. *Injury* 2021 **52** 1606–1613. (<https://doi.org/10.1016/j.injury.2020.12.028>)
- 194. Quinnan SM & Lawrie C.** Optimizing bone defect reconstruction—balanced cable transport with circular external fixation. *Journal of Orthopaedic Trauma* 2017 **31** e347–e355. (<https://doi.org/10.1097/BOT.0000000000000994>)